ICCS
International Clinical Cytometry Society

Sponsored and reviewed by ICCS Quality and Standards Committee

Title: TRBC1 Validation - Practical Guidance

Authors: Andrea Illingworth, Dahl-Chase Dx Services
Allyson Wong, Lahey Hospital & Medical Center
Katherine Devitt, University of Vermont Medical Center
Weijie Li, Children's Mercy Hospital
Felipe Magalhães Furtado, Grupo Sabin and Hospital da Criança de Brasília
Jean Oak, Stanford University
Xuehai Wang, The University of British Columbia
Wolfgang Kern, MLL Münchner Leukämielabor

Date: Aug 8, 2023

INTRODUCTION

T-cell lymphomas encompass a wide spectrum of hematologic entities. They can manifest in the blood, bone marrow, lymph nodes, intestines, liver, spleen and skin, among others. In the 2022 classification, the WHO increasingly defines hematologic entities based on genetic alterations, however, this does not apply to T-cell lymphomas. Instead, the WHO classifies 36 different T-cell and NK-cell entities by site of presentation or current understanding of defined T-cell subsets such as cell-of-origin or shared morphologic and immunophenotypic features (Alaggio et al., 2022). In addition, in 2022, the International Consensus Classification (ICC) was established, in which eight subgroups were proposed as provisional entities within T-acute lymphoblastic leukemia (T-ALL), mainly based on specific rearrangements (Arber et al., 2022).

T-cell neoplasms are diagnosed based on their clinical presentation and history along with results from histologic and flow cytometric studies (Horna, Shi, Olteanu, et al., 2021). One essential problem in the diagnosis of T-cell lymphoma is the lack of reliable immunophenotypic markers to detect clonality within neoplasms of the T-cell lineage (Tan et al., 2006). This is one reason why molecular techniques like polymerase chain reaction (PCR) and targeted next generation sequencing (t-NGS) play a major role in diagnostics of T-cell lymphomas, as their mutation profile provides a reliable basis for diagnosis (Syrykh et al., 2021; Tan et al., 2006). Nevertheless, the use of PCR harbors problems, since not all T-cell lymphomas show a clone detectable by PCR (Tan et al., 2006). In addition, the detection of clonality does not necessarily prove the presence of neoplasia, since it may also appear temporarily in infections, immunodeficiency, and autoimmune disorders. In these cases, molecular assays can lead to false positive results (Horna, Shi, Olteanu, et al., 2021). In such situations, a control should be performed after 2-3 months. If clonality is no longer detectable after this time, a neoplasm is improbable. For routine diagnostics, a method that is easy to establish, or even better, a simple extension of a method already in routine use, would be time and cost efficient.

The importance of T-cell receptor (TCR) gene rearrangements in diagnostics is well established. Somatic modification of the germline configuration of TCR genes to a unique configuration is fundamental for the development of a T-cell clone with an extracellular receptor specific for a

particular antigen (Bertness et al., 1985; Mahe et al., 2018). The TCR is a heteroduplex molecule that is anchored to the outside of the T-cell surface. There it recognizes antigens with high specificity in cooperation with other signaling and structural proteins. The number of TCR-encoding gene regions for specific TCRs in the germline, as well as the ability of the TCR gene loci to undergo somatic restructuring, are the basis for the specificity and the variety of potential antigen epitopes that can be recognized by the T-cell population. TCR assays provide molecular genetic evidence of clonality and can facilitate MRD assessment (Mahe et al., 2018).

Despite all described approaches, diagnostics and detection of clonality in T-cell lymphomas via immunophenotyping has remained a challenge so far, but there is a new attempt involving the T-cell receptor constant β chains (TRBCs) with great potential that we would like to describe here and validate as an immunophenotypic tool in the following pages.

A few years ago, a monoclonal antibody specific for TRBC1 was discovered. Following this, a flow cytometric strategy to assess T-cell clonality by addition of a single anti-TRBC1 antibody to a diagnostic flow cytometry T-cell panel was introduced in 2020 (Shi et al., 2019). TRBC1 is one of two mutually exclusive TRBCs. The addition of the antibody contributes to the detection of T-cell neoplasms and provides the possibility to detect clonality within immunophenotypically distinct $CD3^+$ T-cell subsets in a rapid, simple and low-cost way. With this method, the involvement of peripheral blood by cutaneous T-cell lymphoma (CTCL) can be detected without separate T-cell clonality assays (Berg et al., 2020; Horna, Shi, Jevremovic, et al., 2021; Horna, Shi, Olteanu, et al., 2021; Shi et al., 2019). Detection of clonality is similar to light chain restriction analysis. The antibody is used to label T-cell populations identified by their aberrant immunophenotype (Horna, Shi, Olteanu, et al., 2021). The benefit of TRBC in immunophenotyping was described involving different T-cell neoplasms and its usefulness to rapid and accurate identification of clonal T-cell populations has been proven in several studies (Berg et al., 2020; Horna, Shi, Jevremovic, et al., 2021; Shi et al., 2019).

Nevertheless, clonality detection using TRBC1 should always be performed in conjunction with multiple other T-cell antigens. Ideally, an 8-10 color flow panel should be used in immunophenotyping, allowing analysis of different T-cell subsets and separation of neoplastic and benign T-cells (Horna, Shi, Olteanu, et al., 2021).

TRBC1 furthermore holds great potential in immunophenotyping regarding automated workflows, which are becoming increasingly important. In this context, researchers led by P. Horna developed a semi-automated analysis technique to detect Sézary cells and segment $CD4^+$ T-cells into immunophenotypically distinct clusters, each tested for clonality based on TRBC1 expression (Horna et al., 2022). Sézary cells are large atypical neoplastic T-lymphocytes occurring in Sézary syndrome (Alaggio et al., 2022). The semi-automated technique described by Horna et al. was superior to traditional gating methods and furthermore improved the unambiguous identification of Sézary cells in the B0-B1 range, which describe states of Sézary cells or atypical lymphocytes in the peripheral blood (Alaggio et al., 2022; Horna et al., 2022). These results also show the promise of immunophenotypic analysis of TRBC1 in diagnostics of T-cell neoplasms.

The following sections of this module attempt to further describe the use of the TRBC1 antibody and provide validation considerations of using TRBC1 in flow cytometry assays.

GENERAL ASSAY DEVELOPMENT AND VALIDATION CONSIDERATIONS

Adding TRBC1 will typically consist of using an "empty slot" in a current validated T-cell panel or reconfiguring a current T-cell panel to accommodate the inclusion of TRBC1. Either scenario constitutes an assay modification process which should follow the recent CLSI H62 guidelines (CLSI, 2021). For some practical guidance, one can follow the ICCS Module 21: *Selection and Validation Strategy for Adding Antibodies to Flow Cytometry Panels* (Shah et al., 2021), as well as other related publications. However, since TRBC1 is a new marker mainly used to assess T-cell clonality which is different from many other immunophenotyping markers, additional work will be required to validate its clinical use. This may include steps such as establishing reference ranges of TRBC1+ percentages in T-cell populations observed in normal donors, confirming its ability to predict clonality, and establishing thresholds for abnormality.

Antibody Panel Design & Selection of Antibody/Fluorochrome Pairing

1. Establishing the T-cell Panel components: TRBC1 is a part of the TCRαβ-CD3 complex only expressed on mature αβ T-cells; γδ T-cells are inherently negative for TRBC1. It is important to exclude the γδ T-cell population in the analysis to avoid erroneously interpreting it as TRBC1-negative clonal T-cells. For this reason, the panel should at the very minimum include CD3 and a mechanism to exclude γδ T-cells, using TCRαβ and/or TCRγδ, or an alternative gating strategy (details in *Gating Strategies* section). The **ideal antibody combination** should include CD45, pan-T-cell markers (CD2, CD3, CD4, CD5, CD7, CD8), TCRαβ and/or TCRγδ, NK-cell markers (CD16, CD56, CD57), to facilitate the separation of T-cell subsets and increase the sensitivity of identifying a clonal T-cell population. As a neoplastic T-cell population may not be identified by a monotypic TRBC1 expression pattern if mixed with normal/reactive T-cells, specific markers on the disease of interest may be included to increase the sensitivity of identifying the clonal neoplastic T-cell population (e.g. CD26 for mycosis fungoides/Sezary syndrome (Horna, Shi, Olteanu, et al., 2021), CD25 for adult T-cell leukemia/lymphoma (Craig & Foon, 2008), CD10 for T-follicular helper cell lymphoma (Craig & Foon, 2008), etc. The evaluation of both surface and cytoplasmic TRBC1 expression has been proven useful for recognizing neoplastic immature T-cells (Horna et al., 2022). Adding cytoplasmic CD3 and TRBC1 may also be useful in the diagnosis of surface CD3-negative mature T-cell neoplasms.

2. Antibody selection: Based on the literature, existing panels, and commercially available antibodies, select the more widely used and validated antibodies needed for the new panel.

3. Antibody Clone selection: The selection of antibody clones should be based on the published data and/or experiments you have performed using multiple clones in comparison. Clone JOVI.1 is the clone used in most published studies (Capone et al., 2022; Delfau-Larue et al., 2000; Horna, Shi, Jevremovic, et al., 2021; Shi et al., 2020). This clone was also used by all participating authors.

4. Fluorochrome selection: Fluorochrome selection is based on the antigen expression on the cells of interest, specific known fluorochrome characteristics, existing panels, and clinical purpose. In general, an antibody against a weakly expressed antigen should be conjugated with a bright fluorochrome, and vice versa. We suggest that the TRBC1 antibody should be conjugated to a fluorochrome which shows good separation between TRBC1-positive cells and TRBC1-negative cells (high signal/noise ratio) which is critical for the assessment of T-cell clonality. In our experience the TRBC1-FITC showed the best S/N ratio although FITC is typically considered a dimmer fluorochrome. Consideration should also be given to spillover/spreading that may reduce the resolution between TRBC1-positive and TRBC1-negative populations. Please see the variety of fluorochrome-antibody pairs in the supplemental case examples.

Antibody Optimization and Performance Verification

This process includes validating the intended use, finding the optimal concentration (or titer) of an antibody, minimizing background fluorescence, and steric hindrance of the antibody. The published literature and the manufacturer's package insert usually provide useful information to guide the design of the staining protocols.

1. Antibody specificity: The specificity of the antibody can be tested using appropriate negative and positive controls. Since the expression of TRBC1 is limited to a subset of αβ T-cells, internal negative and positive controls are easily found in most specimens (Figures 1 and 2). The γδ T-cells can be detected in the majority of the specimens and they can be used as a CD3+ T-cell negative control (Figure 2)

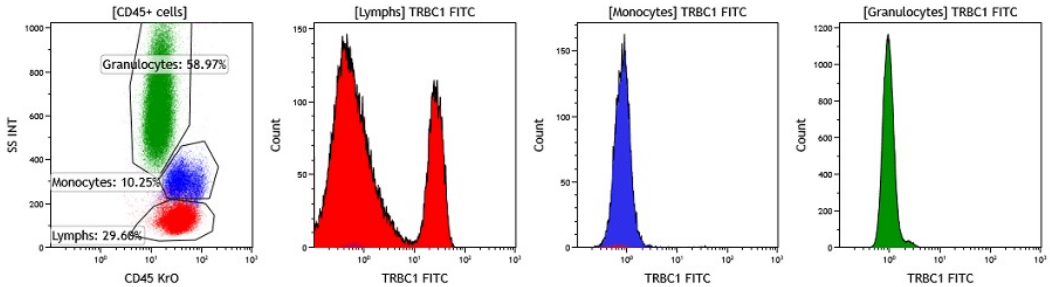

Figure 1A. Bimodal expression of TRBC1 is seen on lymphocytes exhibiting both a TRBC1-negative and TRBC1-positive peak. Only a TRBC1-negative peak is shown for Monocytes and granulocytes. TRBC1 clone JOVI.1 by Caprico Biotechnologies.

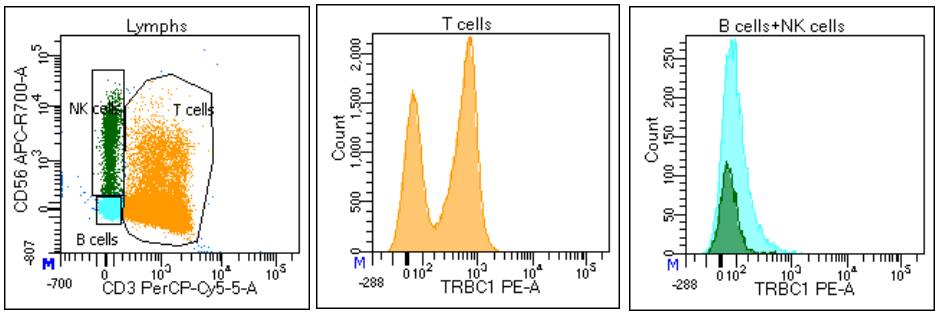

Figure 1B. Bimodal expression of TRBC1 is seen on CD3+ T-lymphocytes exhibiting both a TRBC1-negative and TRBC1-positive peak. Only a TRBC1-negative peak is shown for CD56+ NK-cells.

2. Antibody titration: Titration is an option for achieving an optimal signal-to-noise ratio (S/N) or staining Index (SI). It also often reduces costs of antibodies. The best titer is determined through a serial dilution and comparing the S/N ratio or the Staining index (SI) to provide objective quantifications of staining performance. Please see more detailed ICCS Quality & Standards Module #7: Quality of Reagents – Monoclonal Antibodies (Hulspas et al., 2018).

3. Performance of the new antibody and new/modified panel: Once the antibody is optimized, the new panel should be tested by comparing the results with those of the existing panel, as well as unstained control, single stained control, and fluorescence minus one (FMO, mixtures of all antibodies except one). These experiments should verify the instrument settings (proper voltage, compensation) and facilitate the identification and investigation of potential problems associated with a panel such as incorrect compensation or suboptimal antibody performance in the fully stained panel, as well as any other issues visible on the dot plot combinations.

POSSIBLE GATING STRATEGIES AND INTERNAL CONTROLS

In contrast to the kappa/lambda assay for B-cell clonality assessment, there is no TRBC2 antibody available at this time, and a TRBC1-negative population on a CD3+ αβ T-cell population is assumed to be TRBC2-positive. Therefore, it is critical to exclude γδ T-cells in the analysis to avoid erroneously interpreting them as TRBC1-negative clonal T-cells. In this section, we will present two gating strategies. The first gating strategy relies on dedicated TCR αβ/γδ antibody(ies) and is our method of choice. This panel approach is strongly recommended as it excludes the γδ T-cells (which would be negative for TRBC1) with high confidence. However, we acknowledge the possibility of other options, which includes the absence of TCR αβ/γδ due to panel constraints. This second panel and gating strategy is less optimal but may be used for panels without TCR αβ/γδ antibody as long as the lab considers its possible limitations. But as stated previously, if at all possible, we strongly recommend to include at least one of the TCR antibodies.

1. Ideal gating: A gate is set around αβ T-cells excluding γδ T-cells (Figure 2), followed by various combinations of the other key antibodies CD2, CD3, CD4, CD5, CD7, CD8, CD10, CD16, CD25, CD26, CD56 and CD57. Most combinations should show polyclonal distributions and serve as internal controls for TRBC1 performance. The CD3 neg/CD56+ population may be used as an internal negative control. Not all of these antibodies may

be used in the same panel but using as many antibody combinations as possible will increase the sensitivity in detecting a possible abnormal population (see examples under case studies in supplementary section).

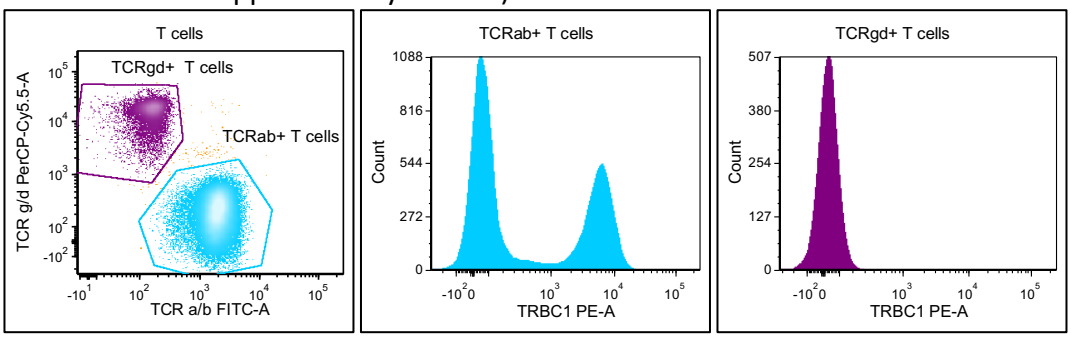

Figure 2. TRBC1 expression on αβ T-cells (polyclonal distribution of TRBC1-negative and TRBC1-positive cells) and γδ T-cells (always TRBC1-negative).

2. Alternative gating: A gate can be set around the CD3+ T-cells, followed by exclusion of the double-negative T-cells and the CD8 dim+ cells which typically represent γδ T-cells. The limitation of this gating is that some αβ cells may be excluded. This plot also includes CD4/CD8 double positive T-cells which may be seen in some samples and are typically polytypic in distribution.

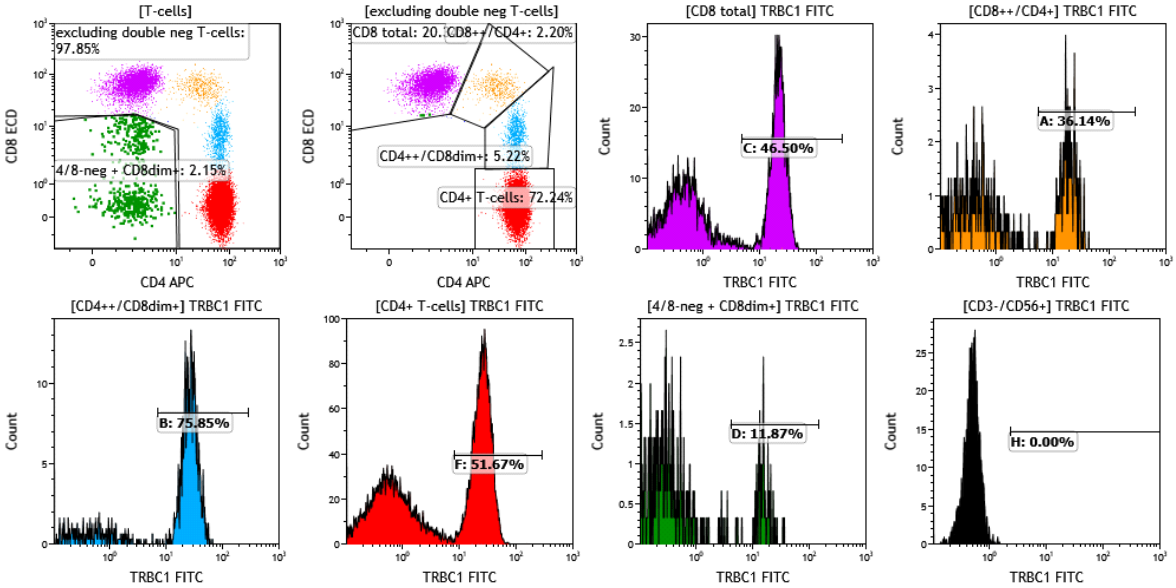

Figure 3. Alternative Gating strategy (gating on CD3+ cells and excluding CD4/CD8 double negative cells) in the absence of αβ and γδ antibodies. Polytypic TRBC1 expression is seen on CD8+/CD4-neg cells (purple), CD4+/CD8 double positive cells (orange and blue), and CD4+/CD8-negative (red). The gate around D4/CD8-negative and CD4-neg/CD8dim+ cells (green) shows mostly TRBC1-negative expression, but may include few T-cells which are αβ+, γδ- T-cells, which would be expected to be polytypic. CD56+/CD3-negative cells (black) should be TRBC1-negative. TRBC1 clone JOVI.1 by Caprico Biotechnologies.

3. Internal Controls: Most samples will have internal control populations which can be used to demonstrate normal polytypic distribution or negative staining for TRBC1. Figure 4

shows various lymphocyte subsets demonstrating expected polytypic staining (CD3+/CD8+ cells and CD3+/CD4+ cells) as well as expected negative staining (CD3-neg/CD56+ cells). Additional gates on other subsets (CD7-/CD26-, CD7-/CD26+, CD7+/CD26-, CD7+/CD26+) can increase sensitivity for the detection of Sézary cells or other types of T-cell neoplasms. Green is a mixture of γδ T-cells and double neg αβ T-cells.

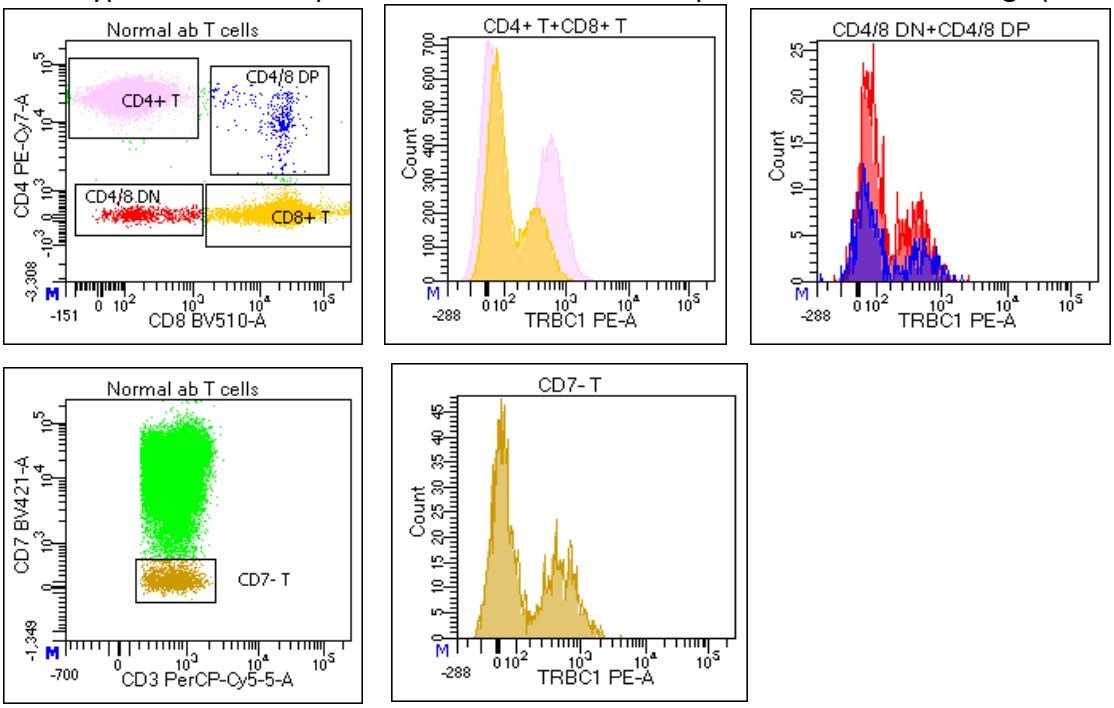

Figure 4. All normal/reactive T-cell subsets display both negative and positive peaks for TRBC1, indicating a polytypic population and confirming the absence of clonality.

Published reference ranges are available for various T-cell subsets, including for age-specific pediatric populations. The lab should consider running the assay on normal/non-neoplastic samples to verify the published reference ranges (summarized in table 1) and establish the cut-off %TRBC1+ that will be considered as abnormal. We recommend a validation cohort with at least 20 "normal" (no reason to suspect a T-cell neoplasm) specimens, recognizing that different regulatory bodies may have different requirements. The 20 specimens should include different tissue types (bone marrow, peripheral blood, lymph nodes, fluids) even though there are no statistically significant differences in %TRBC1+ populations in these samples (Shi et al., 2019). It should be noted that occasional small CD8+ T-cell subsets with a unimodal TRBC1 expression pattern can be detected, and the clinical significance of this finding is unknown (see section Interpretation of Results and Reporting Considerartions). Moreover, since T-cells are heterogenous with multiple normal/reactive subsets, and the subsets have different %TRBC1+ reference ranges (Muñoz-García et al., 2021), a separate cut-off for each subset could be optional.

Tαβ-Cell Subset	% TRBC1⁺ Cells *		TRBC1⁺/TRBC1⁻ Ratio		Probability (%) of Finding A Clonal Tαβ Expansion When TRBC1⁺/TRBC1⁻ Ratio is Outside the Range Mean ± 3 SD (ρ-Value)
	Mean ± 1 SD	Range (Mean ± 3 SD)	Mean ± 1 SD	Range (Mean ± 3 SD)	
Tαβ cells	40 ± 6.7	20–60	0.66 ± 0.071	0.25–1.4	
Tαβ CD4⁺	43 ± 6.3	24–62	0.75 ± 0.067	0.31–1.6	
Tαβ CD8⁺	35 ± 8.8	8.3–61	0.53 ± 0.096	0.091–1.6	99.73% (<0.001)
Tαβ DP	36 ± 12	1.6–71	0.57 ± 0.13	0.016–2.5	
Tαβ DN	29 ± 10	0-61	0.41 ± 0.12	0–1.5	

Table 1. Ranges for polytypic (normal/reactive) total αβ T-cells and major subsets in peripheral blood (n=83) as defined as the mean %TRBC1+ and the mean TRBC1+/TRBC1- ratio ± 3 standard deviation (SD) (Muñoz-García et al., 2021).

Validation of αβ T-Cell Clonality Assessment by TRBC1 Expression

The necessary components of the validation will vary depending on the manner in which TRBC1 is being introduced. Many labs will have an already-validated T-cell panel in which they wish to add to or exchange a marker for TRBC1 (assay modification). Some labs will want to validate an entirely new panel as part of a new assay validation. Much detail regarding the different components has been covered in other ICCS Q&S modules such as Module 21 "Selection and Validation Strategy for Adding Antibodies to Flow Cytometry Panels" and Module 25 "A summary of validation considerations with real-life examples using both qualitative and semiquantitative flow cytometry assays". (Oldaker et al., 2022; Shah et al., 2021). For reference, the general components of a validation are listed in Table 2, with TRBC1-specific details explained below. Please note, all sample sizes are referencing a suggested minimum and may need to be adjusted to the lab-specific setting.

Accuracy	At least 20 samples with a mixture of normal and abnormal
Precision	Varies Intra-assay (repeatability): 6 samples, 3 replicates Inter-assay (reproducibility): 2-3 samples, 3 replicates
Detection Capability (analytical sensitivity)	Not required for assay modification
Diagnostic sensitivity	Use accuracy data set, 2x2 table
Diagnostic specificity	Use accuracy data set, 2x2 table
Selectivity (analytical specificity)	Summarize panel design, antibody-fluorochrome choice, gating strategies, etc.
Stability	Sample not required for assay modification, reagent cocktail stability experiments required
Reference Intervals	Not required for qualitative assays

Table 2. Components of validation/verification to consider in assay modification.

1. Accuracy: Although each lab has a different composition of frequently tested specimen types, it is recommended that 20 samples from various tissue types representing a spectrum of disease types as well as normal specimens should be tested (CLSI, 2021). The positive specimens should be CD3+ TCRαβ+ with a clear pathologic diagnosis of T-cell lymphoma/leukemia, and they should include both TRBC1+ and TRBC1- cases. Ideally, the positive cases should have confirmed clonality by other ancillary testing strategies such as TCR gene rearrangement results or TCR Vb flow cytometry assay and/or a confirmed clinical diagnosis of a T-cell neoplasm. If this is not possible, correlational studies with other labs with a validated TRBC1 panel should be considered. Desirable criteria for acceptance include at least 95% concordance.

2. Precision: Depending on the extent and type of validation (new validation vs method modification to include TRBC1 into an already validated panel), the requirement for precision experiments may vary. See Table A6 in CLSI H62 for further guidance (CLSI, 2021) and suggested number of samples and replicates. The final decision for the extent of precision experiments lies with the medical director of the laboratory.

3. Diagnostic sensitivity and specificity: Using the accuracy dataset, create 2x2 concordance tables to determine diagnostic sensitivity and specificity (CLSI, 2021; Oldaker et al., 2022).

4. Selectivity: Much of the work required for demonstrating that the antibodies and panels are identifying the targeted populations of interest occurs during panel design, antibody selection, clone choice, and antibody titration. Antibody specificity sheets are a useful tool, and an example of a TRBC1 antibody specificity sheet is shown in Figure 5. All of the decisions regarding the antibody/clone choice should be summarized within the validation summary.

Antibody Specificity Verification

Antibody:	TRBC1			Vendor:	Caprico Biotechnologies	
Fluorochrome:	PE			Catalog #:	4133022	
Panels:	T-CLPD			Clone:	JOVI.1	
Use:	Identify T-cell clonality			Isotype:	IgG2a	
Sample #	Expected Positive Expression	Actual Results	Pass/Fail	Expected Negative Expression	Actual Results	Pass/Fail
FC-23-107	Subset reactive T-cells	Positive	Pass	Subset reactive T-cells; B-cells	Negative	Pass
FC-23-115	Subset reactive T-cells	Positive	Pass	Subset reactive T-cells; B-cells	Negative	Pass
FC-23-151	TRBC1+ Neoplastic T-cells	Positive	Pass	B-cells, NK-cells	Negative	Pass
FC-23-187	X	X	Pass	CD3-negative TCLPD	Negative	Pass
Comments:	TRBC1-PE marks as expected					
Evaluation Date:	3/23/2023			Tech:	XX	
Medical Director:	XX					
			Titration**			
Manufacturer Volume/Test (uL):	5			Date:	2/6/2023	
Number of Tests:	50			Tech:	XX	
Amount provided (ug):	0.2			Titered Volume:	XX	
Total Volume (mL):	250					
Concentration (ug/mL):	50					
**Refer to titration experiment						

Figure 5. An example of an Antibody Specificity Sheet for TRBC1 antibody.

5. <u>Detection Capability Sensitivity (lower limit of detection)</u>
   These panels are primarily used for detecting clonality in cases suspected of having a T-cell abnormality, and not intended to be used as a screening panel. The TRBC1 findings should not be interpreted in isolation, but rather in the context of the additional immunophenotypic features. It should be noted that the LOB, LOD, and LLOQ are challenging to define for these assays due to the fact that there are many variations in abnormal T-cell phenotypes and it is often difficult to separate "normal" from "abnormal", as reported for assays for other diseases designed to detect minimal residual involvement. If the panel is used for monitoring therapeutic response or screening purposes, the sensitivity should be established following rare event detecting SOPs, but this is outside the scope of this module.

TRBC1 VALIDATION – A PRACTICAL EXAMPLE

We describe a validation of the TRBC1 FITC antibody using ammonium chloride lysis with analysis on two Beckman Coulter Navios flow cytometers using 10 color analysis. Deciding whether to incorporate the new antibody into one of our current T-cell panels or designing a new panel was the first step. One of our T-cell panels is a screening T-cell tube with CD2, CD3, CD4, CD5, CD7,

CD8, TCRαβ, TCRγδ, CD56, and CD57. Since TRBC1 is only found on αβ T-cells, the decision was made to keep the screening tube intact and create another tube with TRBC1. In our workflow, an aberrant phenotype, morphology, or clinical information prompts additional workup with CD26 for Sezary cells, CD25 for adult T-cell lymphoma, CD28 for T-LGL leukemia, and now TRBC1 for clonality.

The TRBC1 antibody was first titrated to determine the optimal staining volume of antibody to use. We stained 4 tubes, each with 100 uL of a peripheral blood with normal complete blood count and differential. The manufacturer recommended a concentration of 5 uL to stain, so the specimen was stained with 2.5 uL, 5 uL, and 10 uL of the antibody and the fourth tube with no antibody to determine the best signal/noise ratio. We found very good signal-to-noise ratio in all of the antibody volumes used and decided to use 2.5 uL of antibody for staining to avoid unnecessary cost. The core group of antibodies in our new 10-color tube includes CD3, CD7, CD5, CD4, CD8, and CD2. Redundancy of antibodies helps to identify the aberrant T-cells found in our screening T-cell tube and the new T-cell tube with TRBC1. The new tube of 10 antibodies includes TRBC1 (FITC), CD1a (PE), CD7 (ECD), CD5 (PC5.5), CD8 (PC7), CD4 (APC), CD2 (APC-Alexa Fluor 700), CD10 (APC Alexa Fluor 750), CD3 (Pacific Blue), and CD45 (Krome Orange). A cocktail of the 10 antibodies was made to allow for quick evaluation of specimens. We used 20 uL of the cocktail with 100 uL peripheral blood and collected data on 20 normal bloods. Additional specimens were tested when there was suspicion of a T-cell aberrancy.

1. Accuracy: Although the majority of our testing will be done on peripheral blood, we also collected data on a few bone marrows. Because of sufficient cellularity, we were also able to test a supraclavicular lymph node, retroperitoneal lymph nodes, a small bowel specimen, and an AP window mass. The small bowel tissue had approximately 55% γδ T-cells, but they were reliably excluded in our TRBC1 evaluation because they were CD4-CD8-. Several pleural fluids were also included in our evaluation. We compared the flow-based TRBC1 results with clinical information, T-cell gene rearrangement testing, and biopsy results. Of the initial 30 samples tested, 8 were found to have clonal T-cells. One of the abnormal patients came to us with a diagnosis from an outside facility, one had inadequate DNA amplification but was independently found to be in agreement with our diagnosis of T-cell lymphoma, two had T-cell gene rearrangement agreement, and one had discordant rearrangement results. Another sample with normal polytypic TRBC1 had been sent for T-cell gene rearrangement and was normal. Testing performed on the normal samples and patients chosen with B cell lymphomas all had normal polytypic TRBC1 expression.

2. Reproducibility/Precision/Stability: Early in our evaluation, we were able to work up a patient with cutaneous T-cell lymphoma (CTCL) and detected the patient's aberrant phenotype with monotypic TRBC1 expression among the normal T-cells expressing polytypic expression. Since the patient was hospitalized, we were able to replicate the data over several days on our two cross-standardized instruments. Working with the CTCL

samples allowed us to optimize the analysis protocol and compensation on both flow cytometers and demonstrate inter-instrument and inter-operator precision.

3. Selectivity: The core group of antibodies in our new 10 color tube includes the pan-T-cell markers CD3, CD7, CD5, CD4, CD8, and CD2. Keeping the same backbone helps identify the aberrant T-cells found in our standard screening T-cell tube and the new T-tube with TRBC1. As noted in the accuracy paragraph, all specimens known to have normal T-cells, expressed normal polytypic TRBC1. Dilutional studies of a peripheral blood with clonal T-cells were performed on both instruments, but we would like to repeat the studies to see how sensitive our procedure might be for rare event analysis.

4. Reporting: We use a cutoff of 90% all-positive or all-negative TRBC1 expression when interpreting clonality. Two lymph nodes with clonal T-cells were both identified by 96.3% and 93.1% negative TRBC1 expression and bloods were either all-negative or all-positive were 100%, 96.3%, 94.8%, 96.6%, 96.6%, 96.0%.

			TRBC FITC	
	SPECIMEN	**DIAGNOSIS**	**% all-neg**	**% all-pos**
1	blood	CTCL	100	
2	blood	CTCL	96.3	
3	axillary node	composite B/T lymphoma	96.3	
4	retroperitoneal LN	PTCL-unspecified	93.1	
5	blood	dual 4+/8+		94.8
6	blood	T-LGL Leukemia		96.6
*7	blood	(dual 4+8+) T-Prolymphocytic Leukemia		96.6
8	blood	CTCL	96	
	7 same patient as 5 but different day	AVERAGE	96.24	
		2 S.D	3.88	

Table 2: Types of samples used for the verification of a cutoff of 90% for clonality

We report TRBC1 as having polytypic or monotypic expression and do not report a percentage. Sufficient normal T-cells are usually found in the sample to show polytypia and serve as an internal normal control. While working with this antibody we have elected not to use the TRBC1 tube unless an aberrancy is seen in the screening tube or if clinical information, i.e. neutropenia, suggests the possibility of abnormal T-cells. This decision was made to prevent finding cases with clonal T-cells of unknown significance.

We found our new TRBC1 tube to be helpful in distinguishing T-LGL leukemia from reactive LGLs since T-LGLL shows clonal monotypia, whereas reactive LGLs are polytypic. TRBC1 has been particularly useful since CD7 or CD26 loss can be seen in reactive T-cells. Over time, our lab has

been able to demonstrate T cell clonality on bloods with cutaneous T-cell lymphoma, T-cell prolymphocytic leukemia, T-LGL leukemia, and peripheral T-cell lymphoma-unspecified. Tissues and a spinal fluid with clonality investigated by flow cytometry correlated with biopsy diagnoses of several angioimmunoblastic T-cell lymphomas, a composite B- and T-cell lymphoma, and a T-cell lymphoma in the CNS.

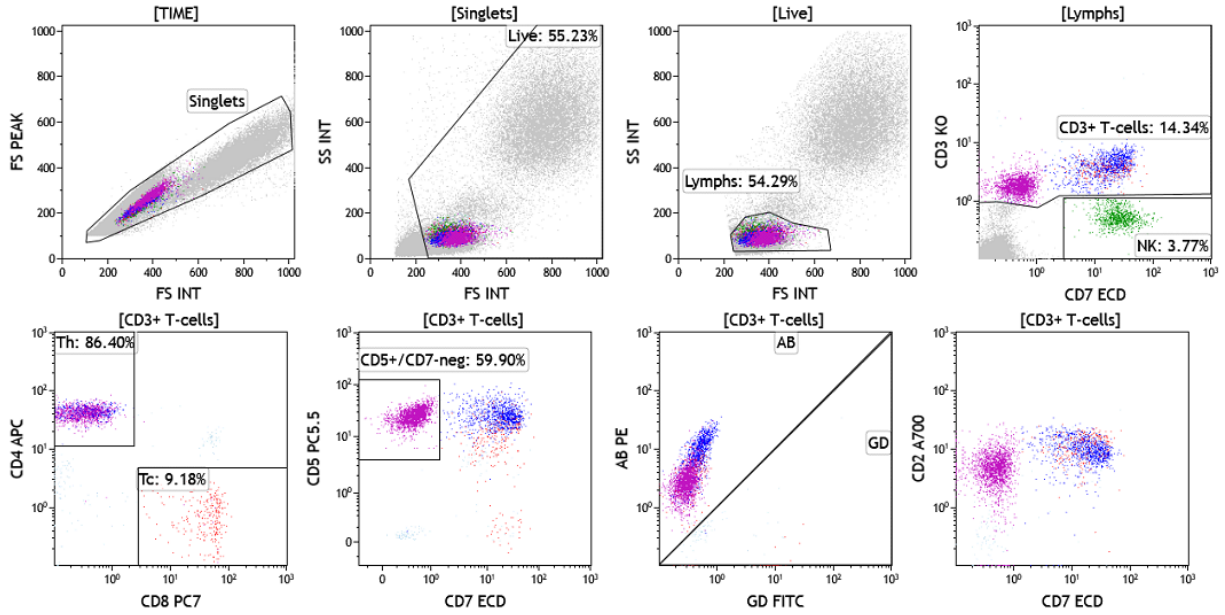

Figure 6. T-cell screening tube containing CD2, CD3, CD5, CD7, CD4, CD8, CD56, CD57, αβ and γδ. This patient has a CD3dim+ and CD2+ (decreased) T-cell population which is positive for αβ and CD4, and has lost CD7 (purple). TRBC1 clone JOVI.1 by Caprico Biotechnologies.

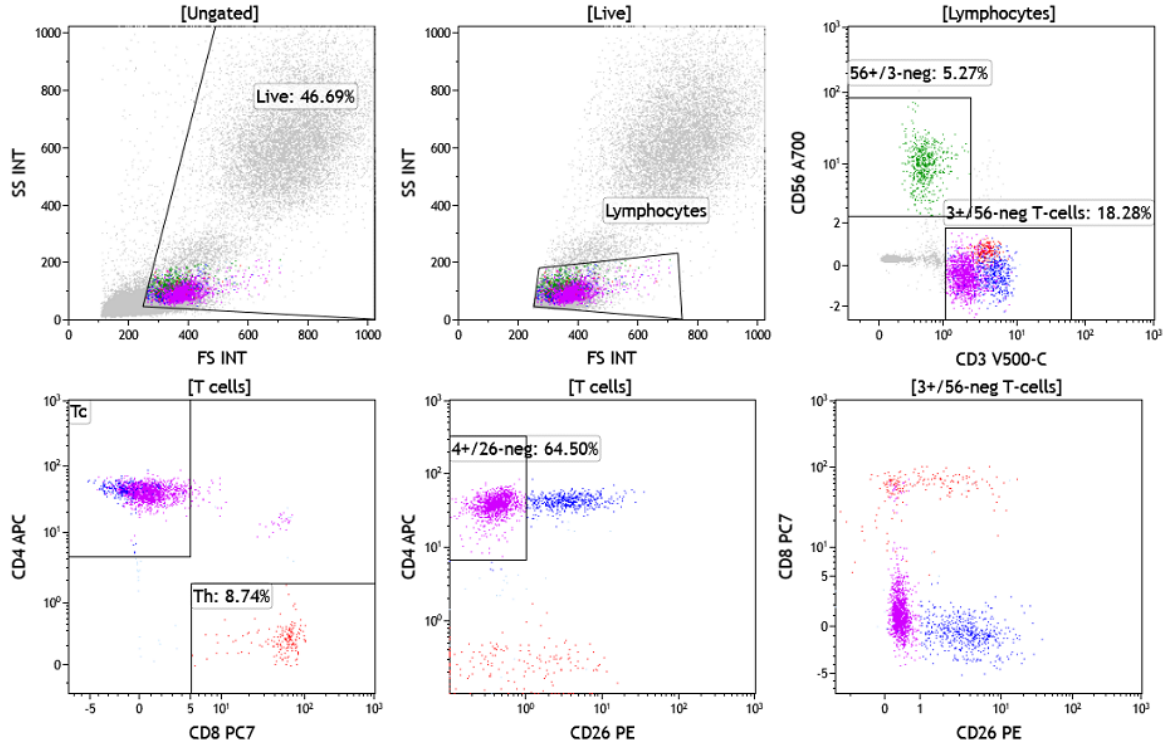

Figure 7. The second T-cell tube shows the CD4+ T-cells have lost CD26 (purple), commonly seen in Sézary cells.

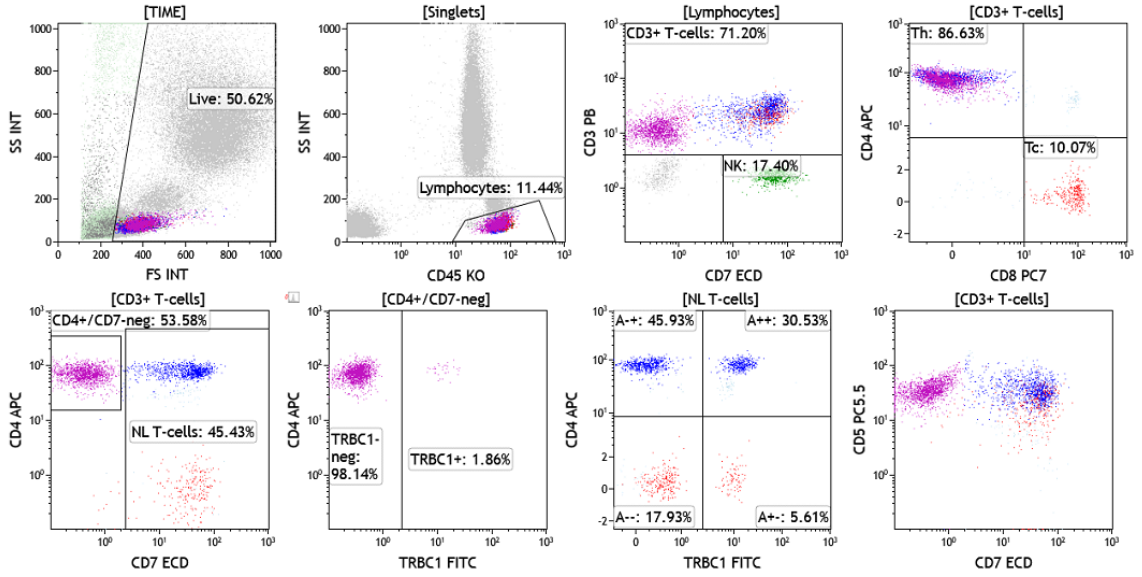

Figure 8. The third T-cell tube contains the T-cell antibodies CD3, CD2, CD5, CD7, CD4, and CD8 as well as TRBC1(FITC), CD10, and CD1a. This sample demonstrates 98.1% of the CD7-negative T-cells are negative for TRBC1 (purple), and are interpreted as clonal. The internal normal T-cells (red and blue) show polytypic distribution.

INTERPRETATION OF RESULTS AND REPORTING CONSIDERATIONS

TRBC1 results are typically reported qualitatively (abnormal versus normal; heterogeneous versus homogenous positive/negative). Reporting the percentage of TRBC1-positive or negative

T-cells is optional. Decreased expression of TRBC1 (i.e. dim-positive expression) is often an indication of a T-cell neoplasm and the percentage and associated phenotype of these cells are recommended to be reported. TRBC1 results are typically reported in conjunction with an abnormal phenotype or a phenotype which is suggestive of an abnormal phenotype. The TRBC1 result is then added as either TRBC1-positive or TRBC1-negative, consistent with (or suggestive of) a clonal process (see individual case studies for a more detailed wording of the TRBC1 results based on the various scenarios.

TRBC1 is highly sensitive in detecting small clonal T-cell populations, however, caution should be exercised when interpreting these populations as some T cell clones may not have clinical relevance and are known as T-Cell Clones of Unknown Significance (T-CUS). T-CUS incidence varies between 6% and 41%, depending on the population studied and methodology used to identify T-cell clonality (Delfau-Larue et al., 2000; Horna, Shi, Jevremovic, et al., 2021). It is significantly more common in patients over 60 years of age (Delfau-Larue et al., 2000). Low-positive results might not be contributory to the overall clinical evaluation or may result in misinterpretation of suspicious morphologic, phenotypic, or clinical findings (Shi et al., 2020). Interpretation of laboratory test results indicative of a T-cell clone remains difficult and occasionally leads to unnecessary laboratory workup or even a misdiagnosis of T-cell neoplasia (Shi et al., 2020). This risk is particularly higher in older patients presenting with unexplained cytopenia with incidental T-cell clones (Chin-Yee et al., 2022). In patients with other hematologic or solid organ malignancies or following organ transplant, oligoclonal reactive cytotoxic T-cell proliferation may be present with homogenous TRBC1 expression (Kroft & Harrington, 2022), which can be misdiagnosed as LGLL. Similarly, CD4/CD8 double-positive clonal T-cell subset should be interpreted in the context of clone size, as clones smaller than 20% of total lymphocytes or 400 cells/µL of blood are highly prevalent in patients without T-cell malignancy (T-CUS, T-cell clones of unknown significance) and found to show no particular disease association (Chin-Yee et al., 2022; Kroft & Harrington, 2022; Shi et al., 2020).

In addition to T-CUS, challenges arise when assessing TRBC1-negative populations. It is important to note that TRBC1 and CD3 are part of the TCRa/b complex and therefore may not be present in abnormal T cell populations that lack surface CD3 or in TCRg/d T cells. In such cases, cytoplasmic TRBC1 has been shown to be useful in detecting abnormal populations that express cytoplasmic CD3 only, or alternative gating strategies utilizing other pan-T cell antigens may need to be employed (Horna, Otteson, Shi, et al., 2021). Like light chain analysis, detecting small abnormal clones may not be possible if screening is solely based on a TRBC1 threshold. Therefore, it's recommended to use TRBC1 in combination with other T-cell antigens to identify abnormal populations (see relevant Case Studies).

Unnecessary work up of small T-CUS commonly encountered in patients with unrelated conditions should be prevented (Shi et al., 2020). In contrast, incidental aberrant CD4+ T-cell populations are rare, but if found, they should raise strong suspicion for clinically significant T-cell neoplasm, and careful evaluation for the possibility of a T-cell lymphoproliferative disorder must be performed irrespective of the clone size (Kroft & Harrington, 2022; Shi et al., 2020).

ICCS
International Clinical Cytometry Society

SUMMARY

Assessing samples for T-cell neoplasms by flow-cytometry has long been problematic. The enviable surface light chains on B-cells rocketed flow cytometry into the spotlight as an essential component in the workup of hematologic samples. Assessment of clonal T-cells has lagged behind, relying on varying levels of marker expression in a "different from normal" capacity, often providing non-specific or equivocal interpretations. The advent of TRBC1 finally brings clonal T-cell assessment by flow cytometry into the spotlight. While there remain pitfalls and shortcomings, the existence of such a marker for assessing T-cell clonality is extremely promising. With TRBC2 on the horizon, the prospect of soon having complementary surface markers on T-cells is realistic. We present this comprehensive summary of TRBC1 and supplemental case examples to familiarize the flow cytometry community with its potential for routine application, provide examples of how to incorporate it into T-cell panels, and to signal caution in interpreting the results in certain diagnostic scenarios where appropriate.

SUPPLEMENTARY SECTION – CASE STUDIES

Case	Diagnosis	Sample	TRBC1	Clonality	Notes
1	ALCL follow-up	PB	Positive	Clonal	
2	Sezary with ALCL	PB	Positive x2	Clonal x2	
3	Sezary with ALCL	PB	Positive x2	Clonal x2	
4	AITL	LN	Negative	Clonal	
5	Pitfall: gd T-cells	PB	Negative	Non-clonal	Illustrates normal gd T-cells negative for TRBC1
6	Sezary	PB	Negative	Clonal	
7	Normal	PB	Polytypic	Non-clonal	
8	T-NHL	LN	Negative	Clonal	
9	APL with TCUS	PB	Negative	Clonal	
10	TCUS?	BM	Dim	?Clonal	
11	TCUS	PB	Positive	Clonal	
12	TCUS	PB	Negative	Clonal	
13	TCUS	PB	Negative	Clonal	PCR confirmed
14	T-ALL	PB	Positive	Clonal	Confirmed on mediastinal biopsy
15	TCUS borderline	Tissue	Negative	Borderline	
16	T-PLL	BM	Negative	Clonal	Confirmed by FISH
17	TCUS borderline	PB	Negative	Borderline	
18	T-LGL	PB	Negative	Clonal	PCR confirmed
19	Reactive T-cells	PB	Polytypic	Non-clonal	
20	AITL & CLL	Tissue	Negative	Clonal	

Reviewed and approved by:
Robert Durso, Regeneron Pharmaceuticals
Lorraine Liu, Vancouver Children's Hospital
David Ng, University of Utah/ARUP Laboratories

Nina Rolf, Vancouver Children's Hospital

For any questions on this module or any other suggestions, please email info@cytometry.org

REFERENCES

Alaggio, R., Amador, C., Anagnostopoulos, I., Attygalle, A. D., Araujo, I. B. de O., Berti, E., Bhagat, G., Borges, A. M., Boyer, D., Calaminici, M., Chadburn, A., Chan, J. K. C., Cheuk, W., Chng, W.-J., Choi, J. K., Chuang, S.-S., Coupland, S. E., Czader, M., Dave, S. S., … Xiao, W. (2022). The 5th edition of the World Health Organization Classification of Haematolymphoid Tumours: Lymphoid Neoplasms. *Leukemia*, *36*(7), 1720–1748. https://doi.org/10.1038/s41375-022-01620-2

Arber, D. A., Orazi, A., Hasserjian, R. P., Borowitz, M. J., Calvo, K. R., Kvasnicka, H.-M., Wang, S. A., Bagg, A., Barbui, T., Branford, S., Bueso-Ramos, C. E., Cortes, J. E., Cin, P. D., DiNardo, C. D., Dombret, H., Duncavage, E. J., Ebert, B. L., Estey, E. H., Facchetti, F., … Tefferi, A. (2022). International Consensus Classification of Myeloid Neoplasms and Acute Leukemias: integrating morphologic, clinical, and genomic data. *Blood*, *140*(11), 1200–1228. https://doi.org/10.1182/blood.2022015850

Berg, H., Otteson, G. E., Corley, H., Shi, M., Horna, P., Jevremovic, D., & Olteanu, H. (2020). Flow cytometric evaluation of TRBC1 expression in tissue specimens and body fluids is a novel and specific method for assessment of T-cell clonality and diagnosis of T-cell neoplasms. *Cytometry Part B: Clinical Cytometry*. https://doi.org/10.1002/cyto.b.21881

Bertness, V., Kirsch, I., Hollis, G., Johnson, B., & Bunn, P. A. (1985). T-Cell Receptor Gene Rearrangements as Clinical Markers of Human T-Cell Lymphomas. *The New England Journal of Medicine*, *313*(9), 534–538. https://doi.org/10.1056/nejm198508293130902

Capone, M., Peruzzi, B., Palterer, B., Bencini, S., Sanna, A., Puccini, B., Nassi, L., Salvadori, B., Statello, M., Carraresi, A., Stefanelli, S., Orazzini, C., Minuti, B., Caporale, R., & Annunziato, F. (2022). Rapid evaluation of T cell clonality in the diagnostic work-up of mature T cell neoplasms: TRBC1-based flow cytometric assay experience. *Translational Oncology*, *26*, 101552. https://doi.org/10.1016/j.tranon.2022.101552

Chin-Yee, B., Suthakaran, A., Hedley, B. D., Howlett, C., Stuart, A., Sadikovic, B., Chin-Yee, I. H., & Hsia, C. C. (2022). T-cell clonality testing for the diagnosis of T-cell large granular lymphocytic leukemia: Are we identifying pathology or incidental clones? *International Journal of Laboratory Hematology*, *44*(6), 1115–1120. https://doi.org/10.1111/ijlh.13949

CLSI. (2021). Validation of Assays Performed by Flow Cytometry, 1st ed. *CLSI Document H62. Wayne, PA: Clinical Laboratory Standards Institute*.

Craig, F. E., & Foon, K. A. (2008). Flow cytometric immunophenotyping for hematologic neoplasms. *Blood*, *111*(8), 3941–3967. https://doi.org/10.1182/blood-2007-11-120535

Delfau-Larue, M. H., Laroche, L., Wechsler, J., Lepage, E., Lahet, C., Asso-Bonnet, M., Bagot, M., & Farcet, J. P. (2000). Diagnostic value of dominant T-cell clones in peripheral blood in 363 patients presenting consecutively with a clinical suspicion of cutaneous lymphoma. *Blood*, *96*(9), 2987–2992.

Horna, P., Otteson, G. E., Shi, M., Jevremovic, D., Yuan, J., & Olteanu, H. (2021). Flow Cytometric Evaluation of Surface and Cytoplasmic TRBC1 Expression in the Differential Diagnosis of Immature T-Cell Proliferations. *American Journal of Clinical Pathology*. https://doi.org/10.1093/ajcp/aqab098

Horna, P., Otteson, G., Shi, M., Seheult, J. N., Jevremovic, D., & Olteanu, H. (2022). Improved semiautomated detection of TRBC-restricted Sézary cells unveils a spectrum of clonal cluster immunophenotypes. *Blood*, *140*(26), 2852–2856. https://doi.org/10.1182/blood.2022017548

Horna, P., Shi, M., Jevremovic, D., Craig, F. E., Comfere, N. I., & Olteanu, H. (2021). Utility of TRBC1 Expression in the Diagnosis of Peripheral Blood Involvement by Cutaneous T-Cell Lymphoma. *Journal of Investigative Dermatology*, *141*(4), 821-829.e2. https://doi.org/10.1016/j.jid.2020.09.011

Horna, P., Shi, M., Olteanu, H., & Johansson, U. (2021). Emerging Role of T-cell Receptor Constant β Chain-1 (TRBC1) Expression in the Flow Cytometric Diagnosis of T-cell Malignancies. *International Journal of Molecular Sciences*, *22*(4), 1817. https://doi.org/10.3390/ijms22041817

Hulspas, R., Keeney, M., Hedley, B., & Illingworth, A. (2018). Quality of Reagents – Monoclonal Antibodies. *ICCS Module 7*.

Kroft, S. H., & Harrington, A. M. (2022). How I Diagnose Mature T-Cell Proliferations by Flow Cytometry. *American Journal of Clinical Pathology*, *158*(4), 456–471. https://doi.org/10.1093/ajcp/aqac079

Mahe, E., Pugh, T., & Kamel-Reid, S. (2018). T cell clonality assessment: past, present and future. *Journal of Clinical Pathology*, *71*(3), 195. https://doi.org/10.1136/jclinpath-2017-204761

Muñoz-García, N., Lima, M., Villamor, N., Morán-Plata, F. J., Barrena, S., Mateos, S., Caldas, C., Balanzategui, A., Alcoceba, M., Domínguez, A., Gómez, F., Langerak, A. W., Dongen, J. J. M. van, Orfao, A., & Almeida, J. (2021). Anti-TRBC1 Antibody-Based Flow Cytometric Detection of T-Cell Clonality: Standardization of Sample Preparation and Diagnostic Implementation. *Cancers*, *13*(17), 4379. https://doi.org/10.3390/cancers13174379

Oldaker, T., Devitt, K., Shah, K., & Illingworth, A. (2022). A summary of validation considerations with real-life examples using both qualitative and semiquantitative flow cytometry assays. *ICCS Module 25*.

Shah, K., Rajab, A., Oldaker, T., Illingworth, A., & Taylor, A. (2021). Selection and Validation Strategy for Adding Antibodies to Flow Cytometry Panels. *ICCS Module 21*.

Shi, M., Jevremovic, D., Otteson, G. E., Timm, M. M., Olteanu, H., & Horna, P. (2019). Single Antibody Detection of T-Cell Receptor αβ Clonality by Flow Cytometry Rapidly Identifies Mature T-Cell Neoplasms and Monotypic Small CD8-Positive Subsets of Uncertain Significance. *Cytometry Part B: Clinical Cytometry*, *98*(1), 99–107. https://doi.org/10.1002/cyto.b.21782

Shi, M., Olteanu, H., Jevremovic, D., He, R., Viswanatha, D., Corley, H., & Horna, P. (2020). T-cell clones of uncertain significance are highly prevalent and show close resemblance to T-cell large granular lymphocytic leukemia. Implications for laboratory diagnostics. *Modern Pathology*, *33*(10), 2046–2057. https://doi.org/10.1038/s41379-020-0568-2

Syrykh, C., Gorez, P., Péricart, S., Grand, D., Escudié, F., Cabarrou, B., Obéric, L., Ysebaert, L., Lamant, L., Laurent, C., Evrard, S., & Brousset, P. (2021). Molecular Diagnosis of T-cell Lymphoma: A correlative study of PCR-based T-cell clonality assessment and targeted NGS. *Blood Advances*, *5*(22), 4590–4593. https://doi.org/10.1182/bloodadvances.2021005249

Tan, B. T., Warnke, R. A., & Arber, D. A. (2006). The Frequency of B- and T-Cell Gene Rearrangements and Epstein-Barr Virus in T-Cell Lymphomas A Comparison Between Angioimmunoblastic T-Cell Lymphoma and Peripheral T-Cell Lymphoma, Unspecified With and Without Associated B-Cell Proliferations. *The Journal of Molecular Diagnostics*, *8*(4), 466–475. https://doi.org/10.2353/jmoldx.2006.060016

CASE 1

Case Description: Peripheral blood submitted for follow-up on ALK+ anaplastic large cell lymphoma

Panel and instrumentation: TRBC1/CD3/CD4/CD5/CD7/CD8/CD45/CD56/TCRαβ/TCRγδ on FACSCanto 10C, specimen was stained first then lysed and washed.

Plot with gating strategy:

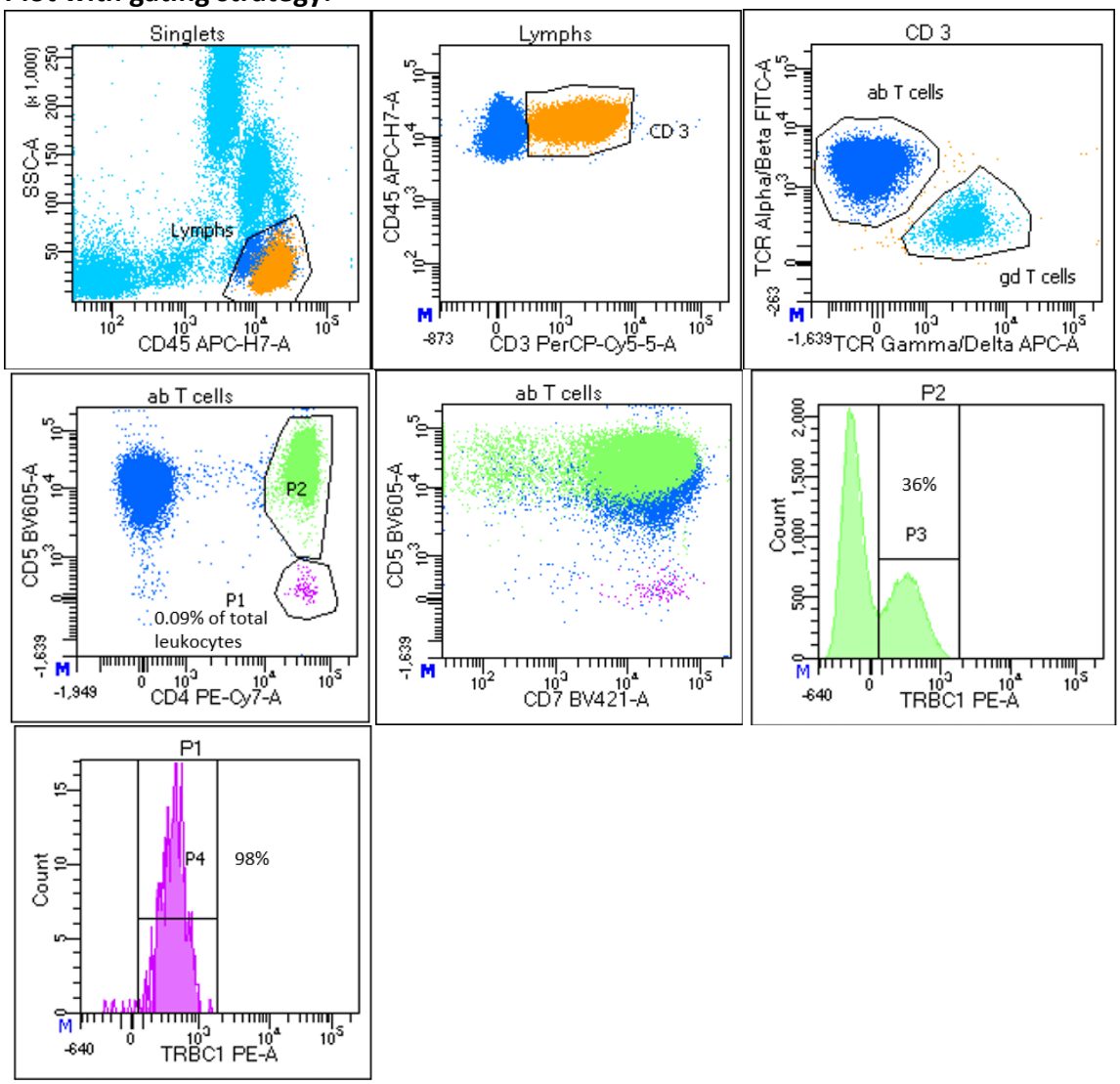

Phenotype: CD3+, CD4+, CD5-, CD7+, CD8-, CD45+, CD56-, TRBC1+

Percent abnormal of total PB cells: 0.09% | **Absolute#:** 394

Clinical Correlation: ALK+ anaplastic large cell lymphoma during therapy

Interpretation: Suspicious for residual ALK+ anaplastic large cell lymphoma

CASE 2

Case Description: Peripheral blood submitted for follow-up of CD4+ Sezary

Panel and instrumentation: TRBC1/CD2/CD3/CD4/CD5/CD7/CD8/CD45/CD56/CD16/CD57/TCRγδ on FACSLyric 12C, specimen was bulk lysed, stained, then washed.

Plot with gating strategy:

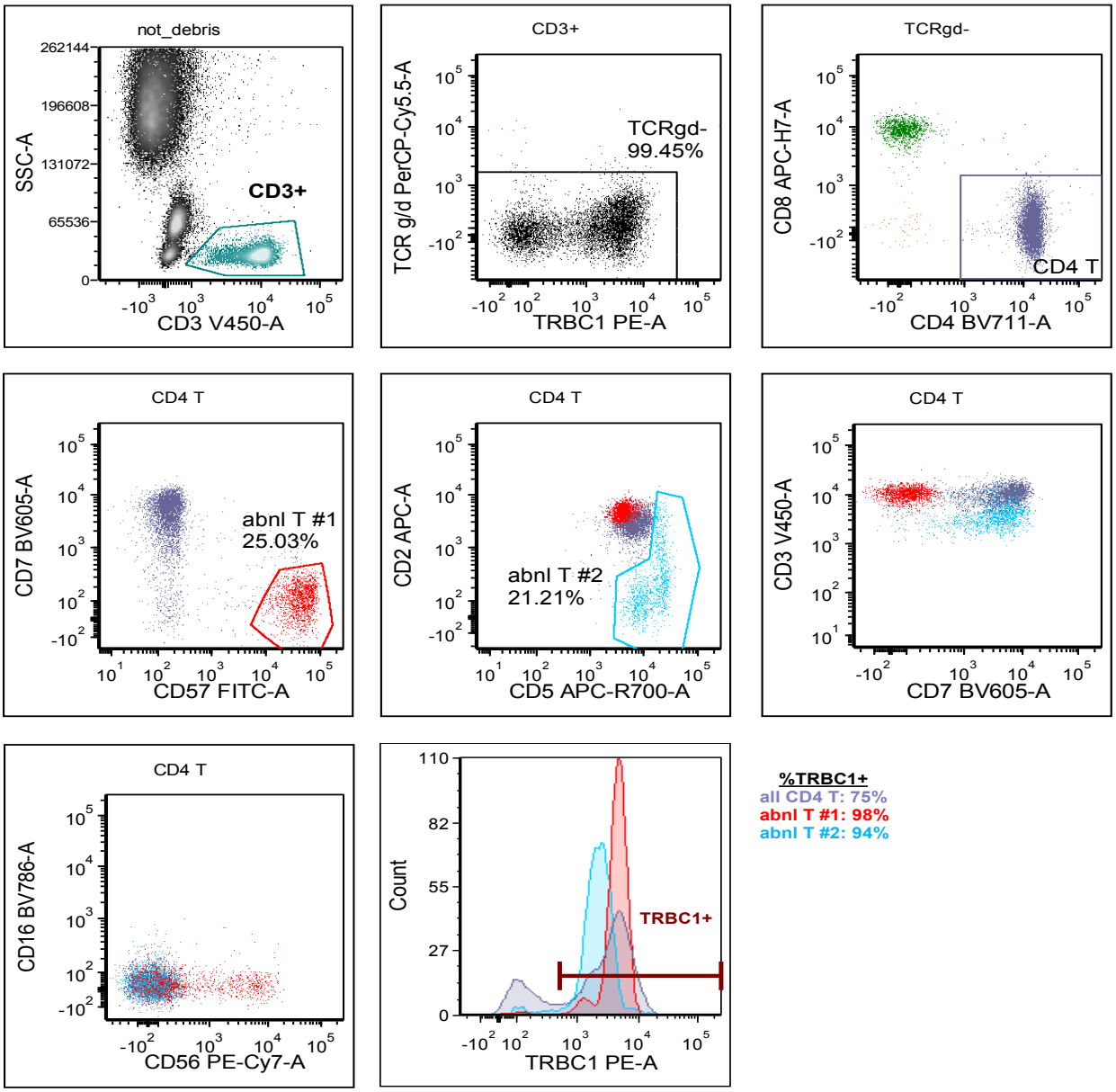

Phenotype:

abnormal #1: CD3+, CD4+, CD2+, CD5+, CD57+, CD56+ (subset), TRBC1+, CD45+, CD7-, CD8-, CD16-

abnormal #2: CD3+ (dim), CD4+, CD5+, CD7+, TRBC1+ (dim), CD45+, CD2-, CD8-, CD56-, CD16-, CD57-

Percent abnormal #1 of total PB cells: 3.6% **Percent abnormal #2 of total PB cells: 3.0%**	**Absolute#:** 394

Clinical Correlation: ALK+ anaplastic large cell lymphoma during therapy

Interpretation: Residual/recurrent Sezary Syndrome

CASE 3

Case Description: Peripheral blood submitted for follow-up of CD4+ Sezary

Panel and instrumentation: TRBC1/CD3/CD4/CD7/CD8/CD26/CD45/CD30/CD25/CD52/CCR4 on FACSLyric 12C, specimen was stained, lysed, then washed.

Plot with gating strategy:

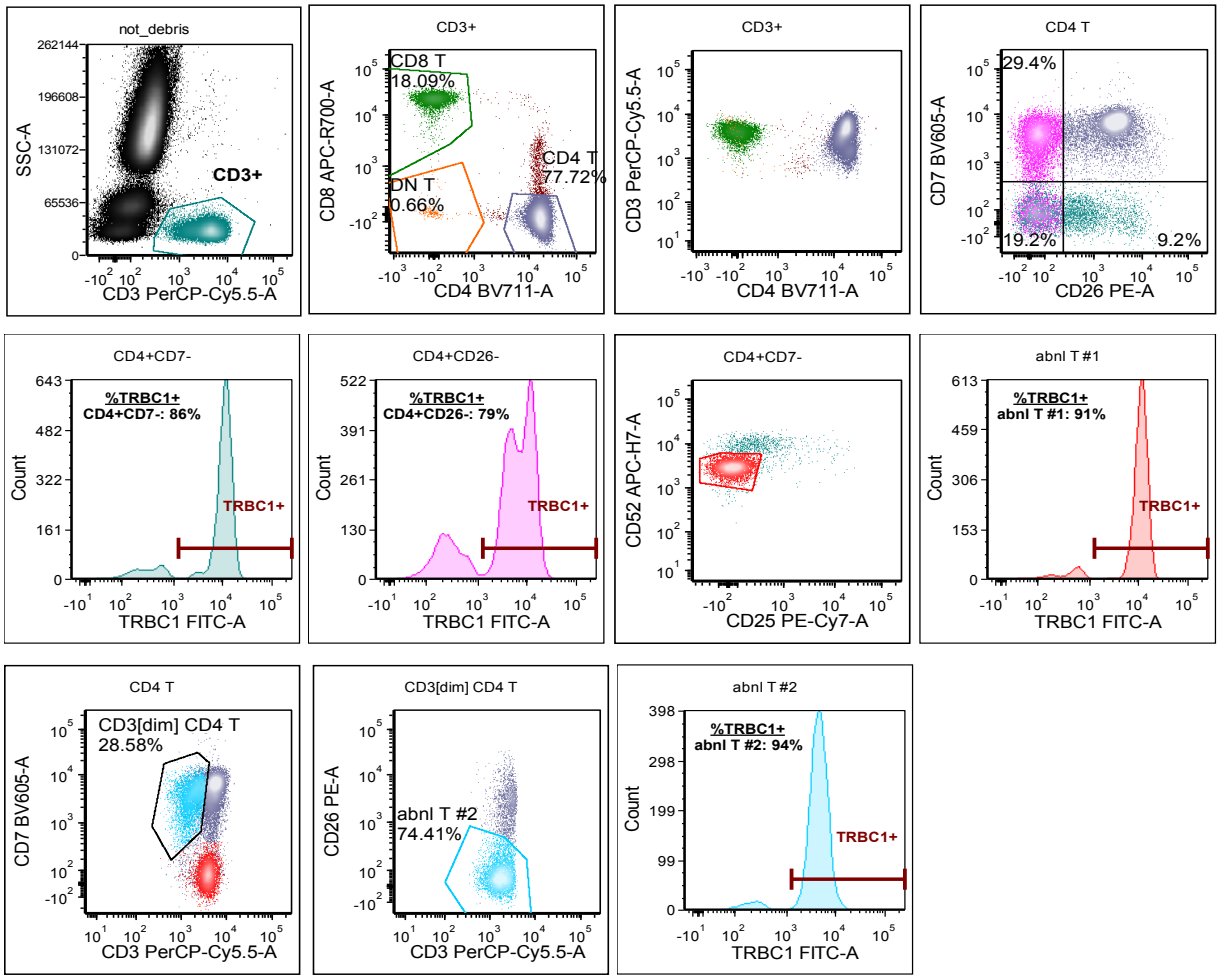

Phenotype:

abnormal #1: CD3+, CD4+, CD26+(var), CD52+(dim), TRBC1+, CD45+, CD7-, CD8-, CD25-, CD30-, CCR4-

abnormal #2: CD3+(dim), CD4+, CD7+, TRBC1+(dim), CD52+, CD25+, CCR4(dim), CD45+, CD26-, CD8-, CD30-

Percent abnormal #1 of total PB cells: 3.6% **Percent abnormal #2 of total PB cells: 3.0%**	**Absolute#:** 394

Clinical Correlation: Sezary syndrome, stage IVA2

Interpretation: 2 abnormal T cell clones consistent with residual/recurrent Sezary Syndrome

CASE 4

Case Description: FNA showing sheets and clusters of small-to-intermediate sized atypical lymphocytes with occasional eosinophils

Panel and instrumentation: TRBC1/CD3/CD4/CD7/CD8/CD26/CD45/CD30/CD25/CD52/CCR4 on FACSLyric 12C, specimen was lysed, washed, stained, then washed.

Plot with gating strategy:

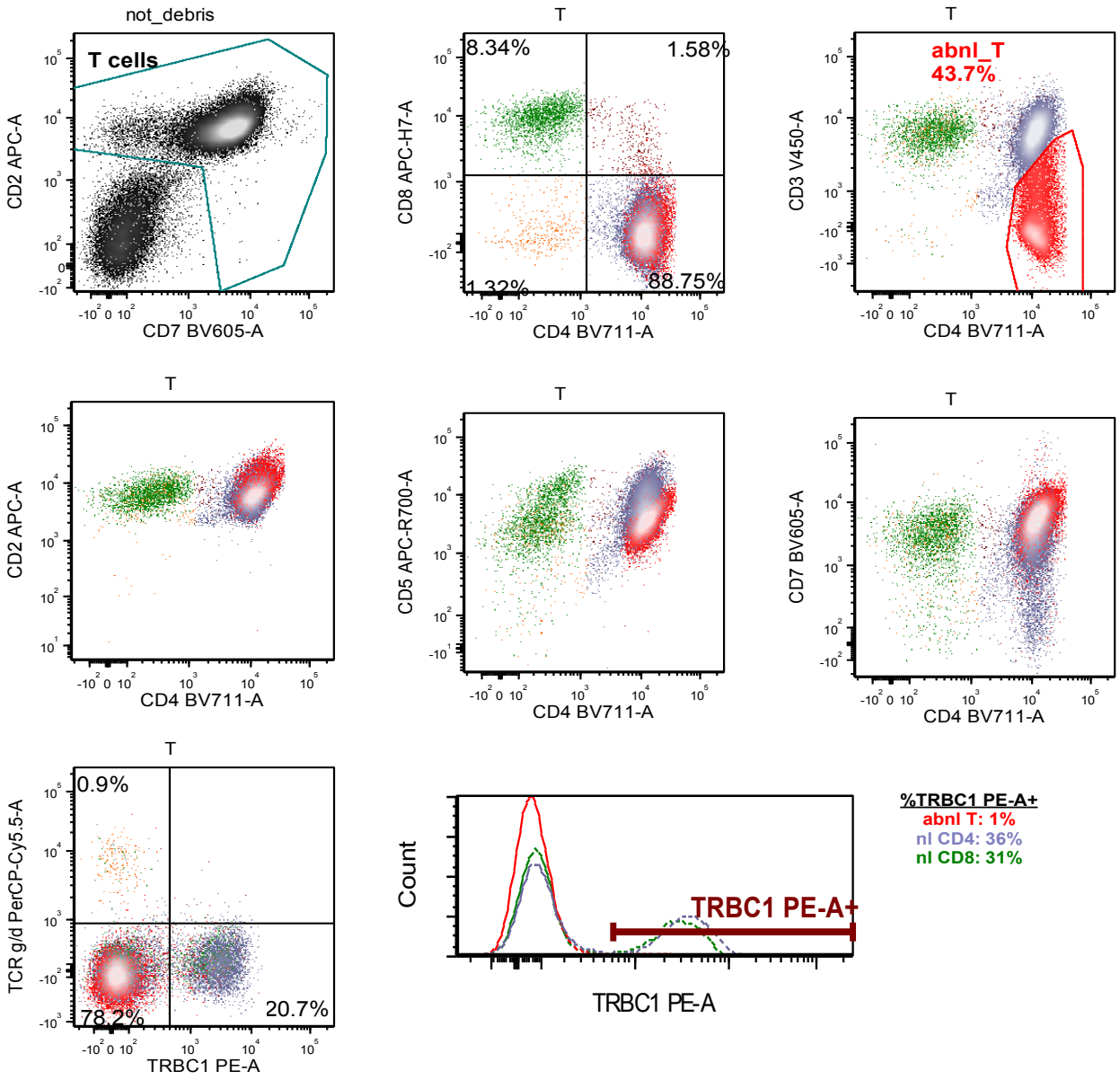

Phenotype: CD3$^{+/-}$, CD2^{+}, CD5^{+}, CD7^{+}, CD10^{partial}, CD20^{partial}, CD200^{variable}, TRBC1^{-}, CD57^{-}, CD56^{-}, CD16^{-}, CD8^{-}, and TCRgd^{-}

Percent abnormal of total CD45+ cells: 26%	**Absolute#:**

Clinical Correlation: Marked lymphadenopathy and B symptoms. T cells are positive for PD1, ICOS, and BCL6 by immunohistochemistry.

Interpretation: CD4+ T cell lymphoma with features suggestive of nodal T-follicular helper cell lymphoma, angioimmunoblastic type.

CASE 5

Case Description: Peripheral blood submitted for investigation of lymph node enlargement

Panel and instrumentation: TRBC1/CD3/CD4/CD5/CD7/CD8/CD45/TCRab. On a separate tube, TCRgd was analysed. 12C Lyric, specimen was stained first then lysed and washed.

Plots:

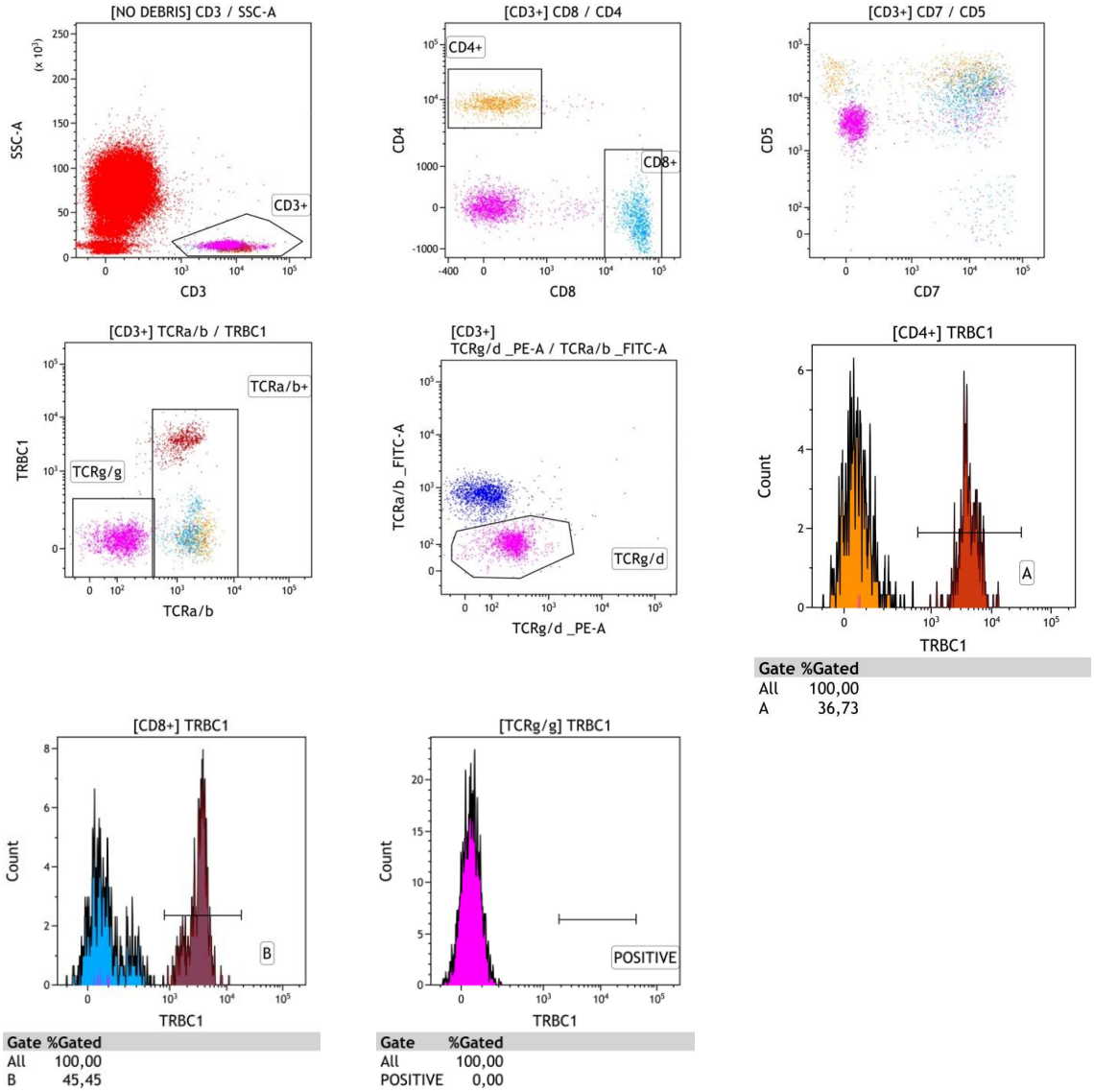

Phenotype: CD2+, CD3 dim, CD4-, CD5 dim, CD7-, CD8-, TCRgd+

Percent abnormal of total pb cells: 1.8% | **Absolute#:** 212

Clinical Correlation: Lymph node enlargement.

Interpretation: Expansion of an abnormal TCRgd T-cell population. TRBC1 is of no value for clonality assessment. It must be assessed by PCR.

CASE 6

Case Description: Peripheral blood submitted for follow up of Sézary Syndrome treatment.

Panel and instrumentation: TRBC1/CD3/CD4/ CD7/CD8/CD26/CD45/TCRab. 12C Lyric, specimen was stained first then lysed and washed.

Plots:

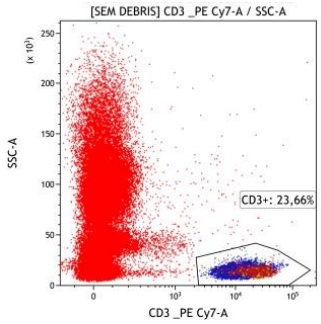

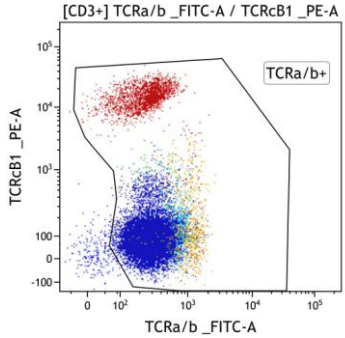

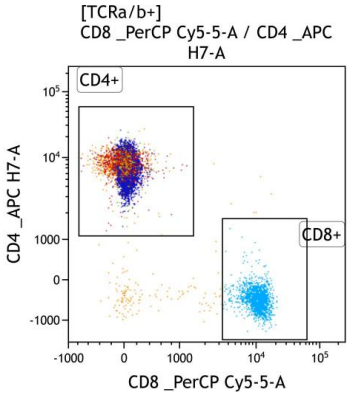

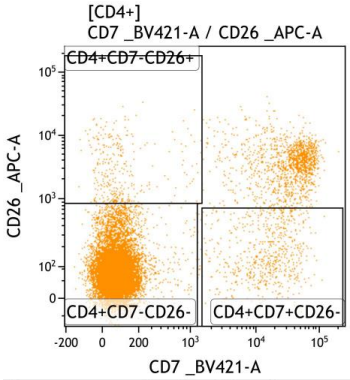

Gate	Number	%Gated
All	16.316	100,00
CD4+CD7-CD26-	13.891	85,14
CD4+CD7-CD26+	325	1,99
CD4+CD7+CD26-	644	3,95

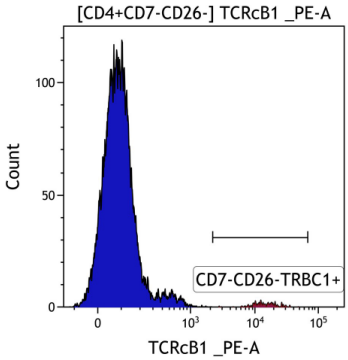

Gate	%Gated
All	100,00
CD7-CD26-TRBC1+	1,40

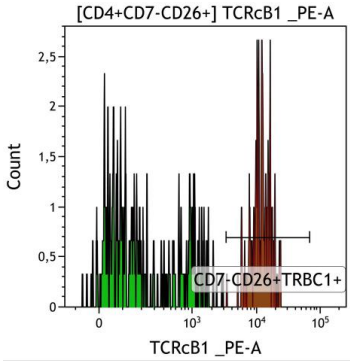

Gate	%Gated
All	100,00
CD7-CD26+TRBC1+	34,77

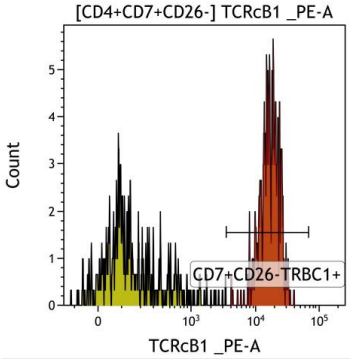

Gate	%Gated
All	100,00
CD7+CD26-TRBC1+	52,33

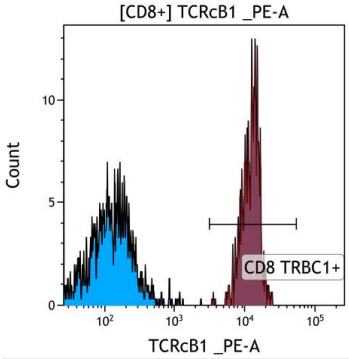

Gate	%Gated
All	100,00
CD8 TRBC1+	41,83

Phenotype: CD3+, CD4+, CD7-, CD8-, CD26-, TCRa/b+, TRBC1-

Percent abnormal of total pb cells: 18.1% | **Absolute#:** 742

Clinical Correlation: Sézary syndrome in treatment.

Interpretation: Sézary syndrome in treatment still with clonal lymphocytes in peripheral blood.

CASE 7

Case Description: Peripheral blood submitted for investigation of LGL leukemia.

Panel and instrumentation: TRBC1/CD3/CD4/ CD5/ CD7/CD8/ CD45/TCRab. 12C Lyric, specimen was stained first then lysed and washed.

Plots:

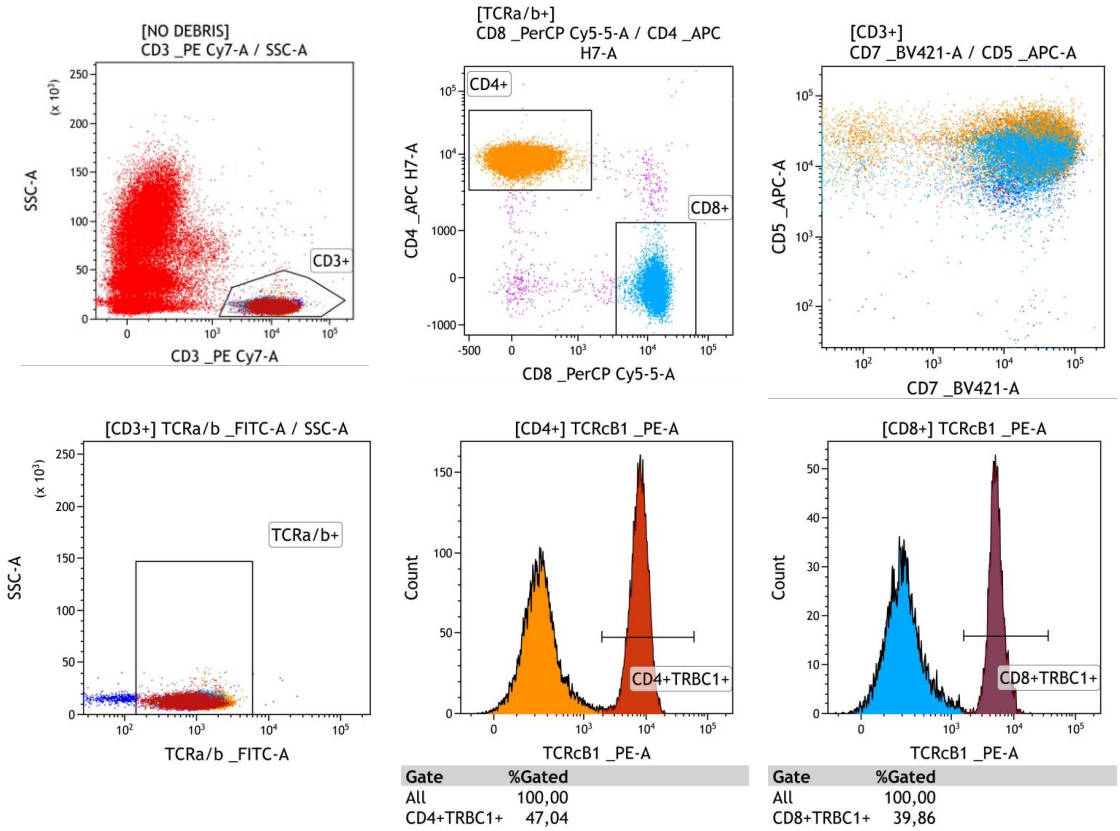

Gate	%Gated
All	100,00
CD4+TRBC1+	47,04

Gate	%Gated
All	100,00
CD8+TRBC1+	39,86

Phenotype: Normal T cells with polytypic TRBC1 expression.

Percent abnormal of total pb cells: 0% | **Absolute#:** 0

Clinical Correlation: Neutropenia is not secondary to LGL leukemia.

Interpretation: No clonal T-cell population identified.

CASE 8

Case 23-0837 Description: Lymph node biopsy in RPMI, submitted for axillary lymphadenopathy

Panel and instrumentation: TRBC1/CD26/CD8/CD3/CD7/CD4/CD56/CD2/CD5/CD45 on 10C Navios, specimen was bulk-lysed, stained and washed

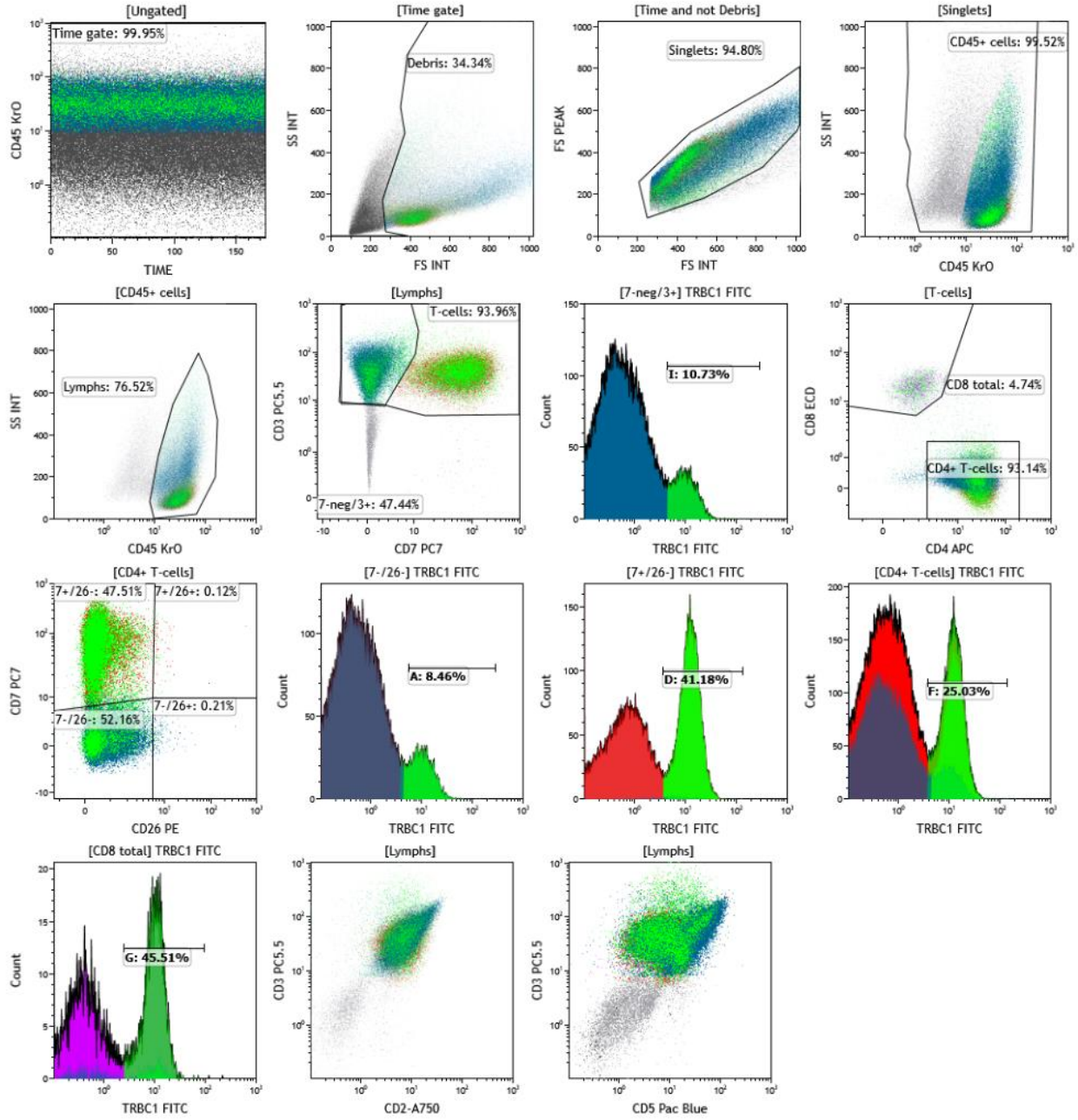

Abnormal Phenotype: CD45+, CD2+, CD3+, CD4+, CD5+, CD7-negative, CD8+, CD26-neg and CD56-neg

Percent abnormal of lymphoid cells: 62%	**Absolute#:** NA

Clinical Correlation: T-cell non-Hodgkin lymphoma (CD30+), immunohistochemical studies demonstrate strong positive staining for CD 3, CD5, CD30, focal positive staining for CD4 and negative results for CD7, CD8, CD10, CD21, BCL-6, CD56, CD20 and Alk-1. Immunohistochemical stain for KI-67 show a high proliferation index (80-90 %).

Interpretation: The abnormal phenotype shows TRBC1 monotypic expression (>90% negative)

CASE 9

Case 23-689 Description: Peripheral blood in EDTA, submitted for pancytopenia

Panel and instrumentation: TRBC1/CD26/CD8/CD3/CD7/CD4/CD56/CD2/CD5/CD45 on 10C Navios, specimen was stained first then lysed with OptiLyse and washed

Plot with gating strategy:

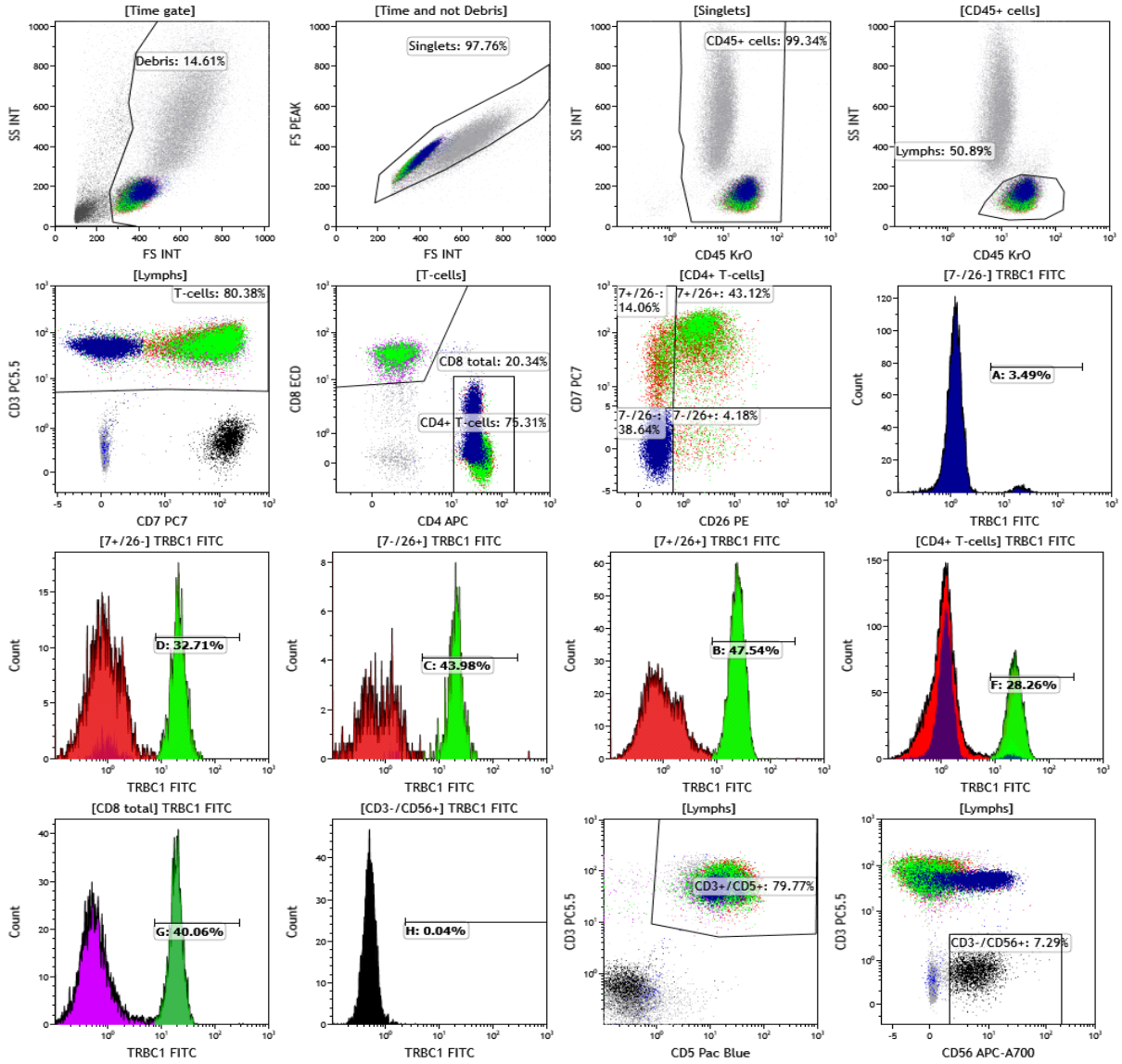

Atypical Phenotype: CD2+, CD3+, CD4+, CD5+, CD7-neg, CD8neg to dim+, CD26-neg and CD56dim+

Percent abnormal of total pb cells: 13.2% | **Absolute#:** 238

Clinical Correlation: Acute promyelocytic Leukemia with PML RaRa fusion

Interpretation: TRBC1 appears monotypic (96% negative). The significance of this finding is uncertain as atypical T-cell populations may be seen in reactive, T-CUS and neoplastic conditions.

CASE 10

Case 23-673 Description: Bone marrow in NaHeparin, submitted for Thrombocytopenia. Hx of NHL s/p ASCT in early 1990s

Panel and instrumentation: TRBC1/CD26/CD8/CD3/CD7/CD4/CD56/CD2/CD5/CD45 on 10C Navios, specimen was bulk-lysed, stained and washed

Plots with gating strategy:

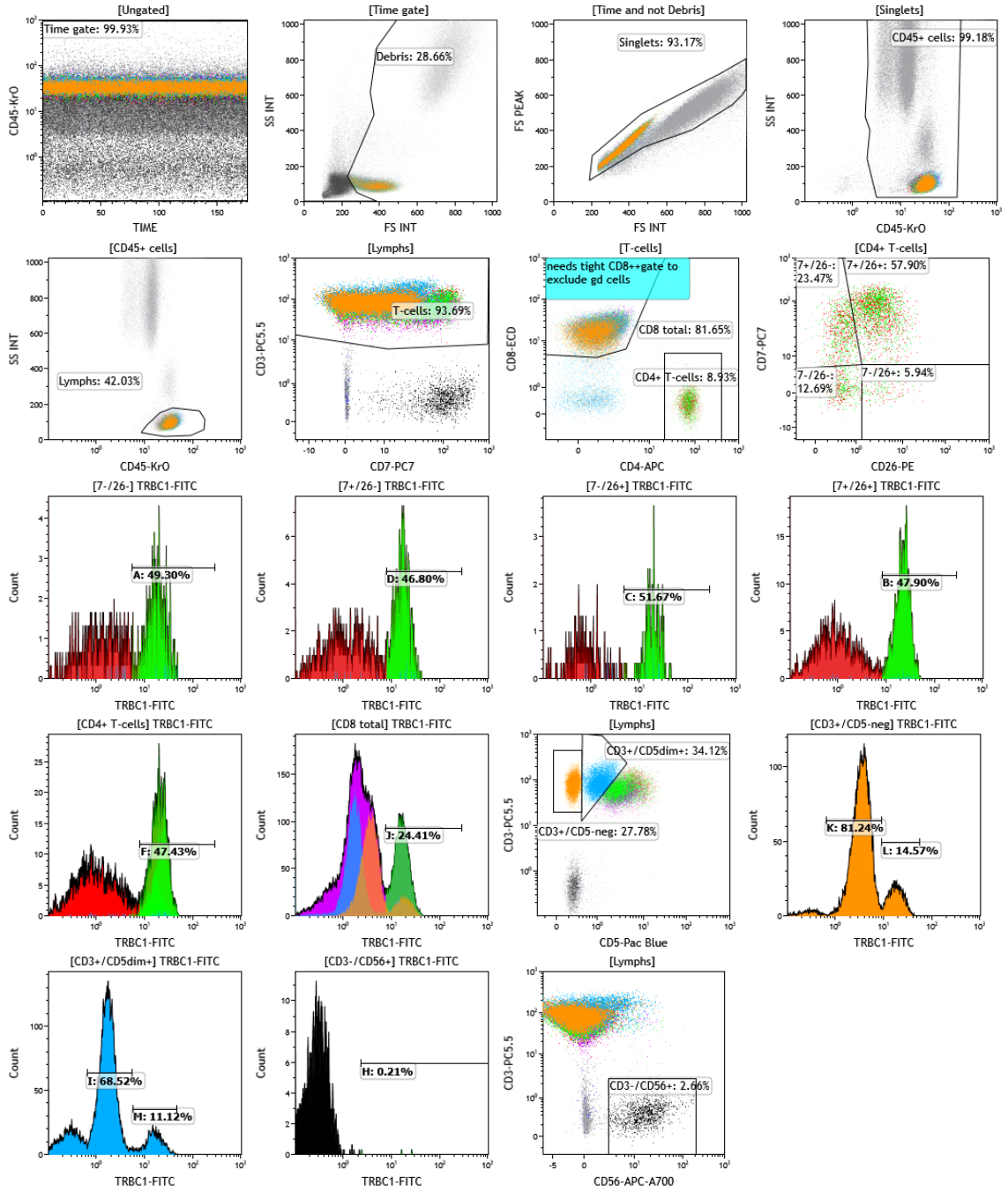

Atypical Phenotype: CD2+, CD3+, CD4-neg, CD5-neg to dim+, CD7-neg to dim+, CD8+ and CD56-neg,

Percent abnormal of total bm cells: 31% | **Absolute#:** NA

Clinical Correlation: Thrombocytopenia, renal disease, COPD

Interpretation: TRBC1 appears to show dim monotypic expression. The significance of this finding is uncertain as atypical T-cell populations may be seen in reactive, T-CUS and neoplastic conditions.

CASE 11

Case 23-625 Description: Peripheral blood submitted for leukocytosis and thrombocytosis

Panel and instrumentation: TRBC1/CD26/CD8/CD3/CD7/CD4/CD56/CD2/CD5/CD45 on 10C Navios, specimen was stained first then lysed with OptiLyse and washed

Plots with gating strategy:

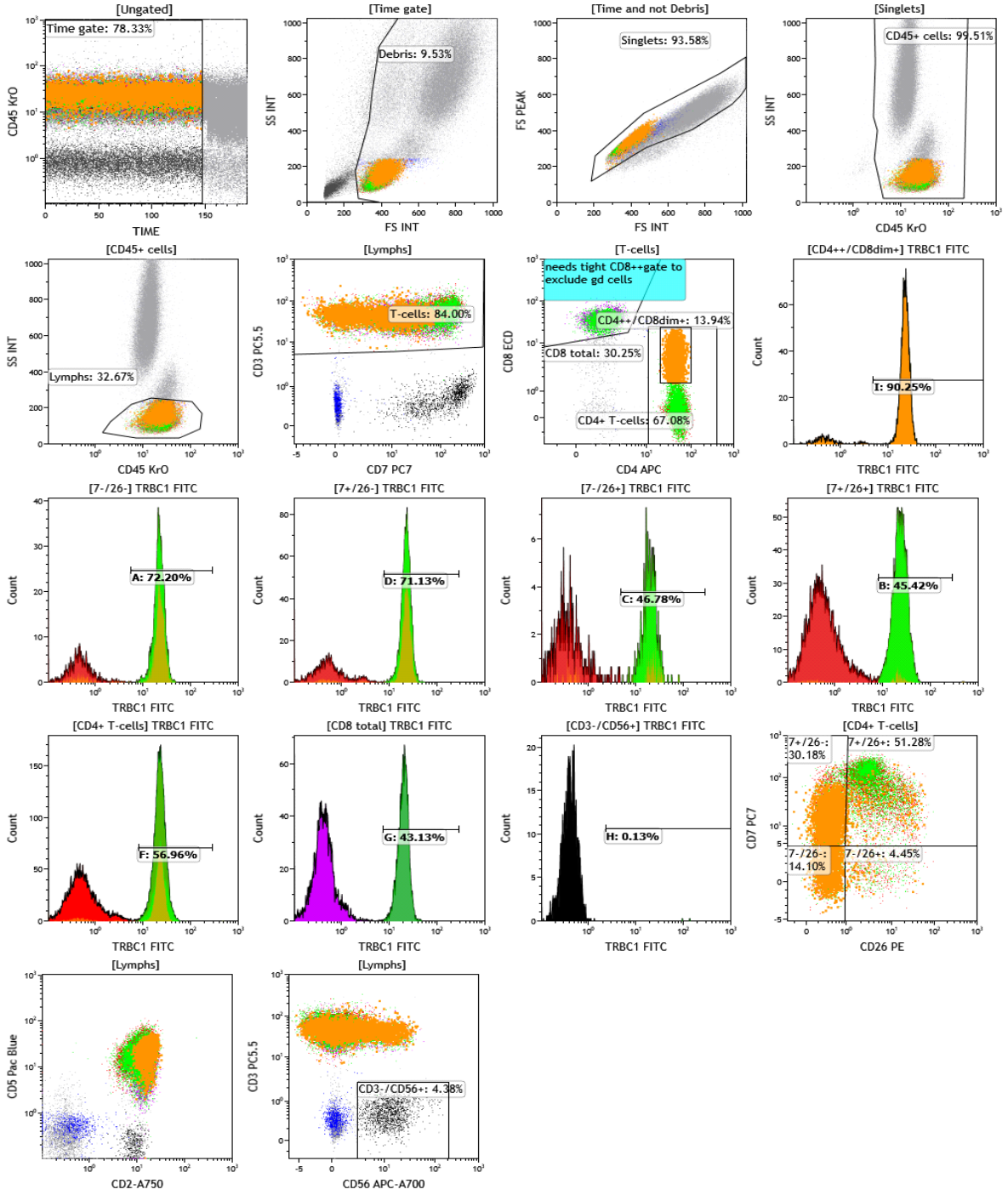

Atypical Phenotype: CD2+, CD3+, CD4+, CD5+, CD7-neg to dim+, CD8dim+, CD26-neg and CD56dim+.

Percent abnormal of total pb cells: 3.9% | **Absolute#:** 480

Clinical Correlation: Leukocytosis, anemia

Interpretation: TRBC1 appeared monotypic (90% positive). The significance of this finding is uncertain as atypical T-cell populations may be seen in reactive, T-CUS and neoplastic conditions.

CASE 12

Case 23-451 Description: Peripheral blood submitted for CLL follow-up

Panel and instrumentation: TRBC1/CD26/CD8/CD3/CD7/CD4/CD56/CD2/CD5/CD45 on 10C Navios, specimen was stained first then lysed with OptiLyse and washed

Plot with gating strategy:

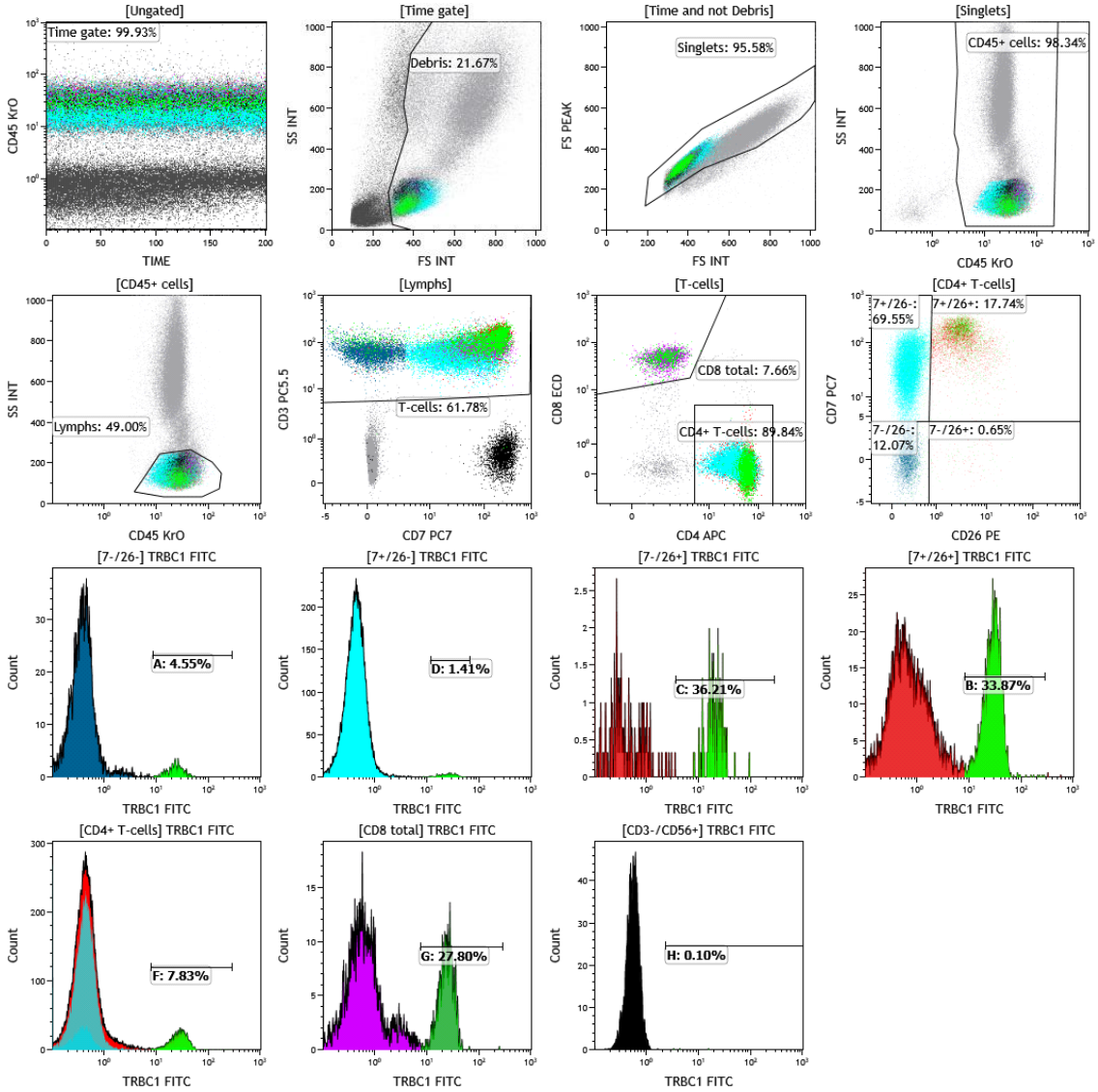

Atypical Phenotype: CD2+, CD3+, CD4+ (decreased), CD5+, CD7-neg to dim+, CD8-neg, CD26-neg and CD56-neg.

Percent abnormal of total pb cells: 19.2%	**Absolute#:** 1,972/cmm

Clinical correlation: B-cell CLL/SLL; incidental finding of T-CUS

Interpretation: TRBC1 appeared monotypic (>95% negative). The significance of this finding is uncertain as atypical T-cell populations may be seen in reactive, T-CUS and neoplastic conditions.

CASE 13

Case 23-431 Description: Peripheral blood in EDTA, submitted for Thrombocytopenia

Panel and instrumentation: TRBC1/CD26/CD8/CD3/CD7/CD4/CD56/CD2/CD5/CD45 on 10C Navios, specimen was stained first then lysed with OptiLyse and washed

Plots with gating strategy:

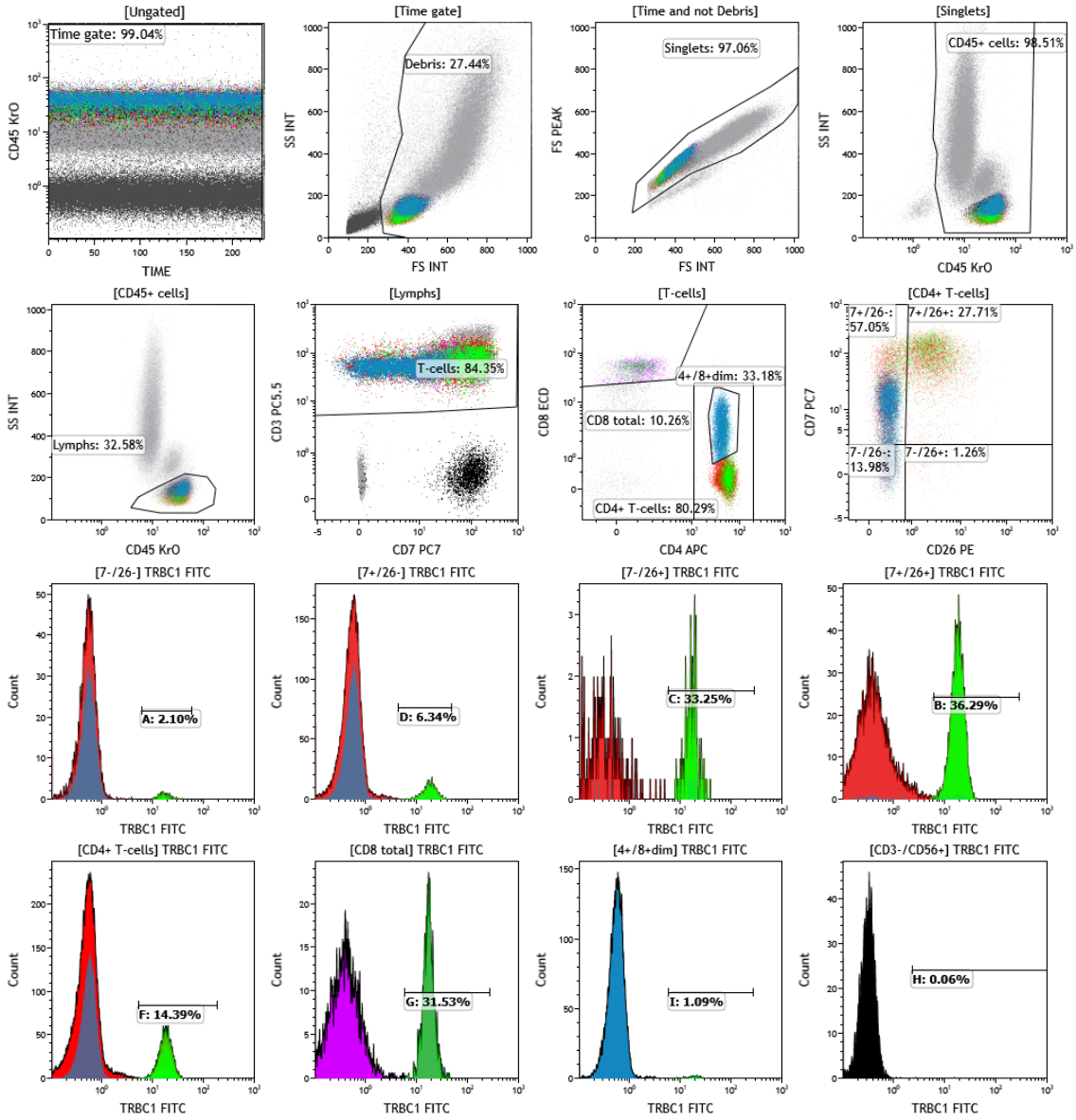

Atypical Phenotype: CD2+, CD3+, CD5+, CD7+ (decreased), CD4+, CD8+ (dim), CD26 neg and CD56 neg.

Percent abnormal of total pb cells: 9.1% | **Absolute#:** 757/cmm

Clinical Correlation: T-cell clonality by PCR-detected, MDS

Interpretation: TRBC1 on the atypical phenotype was monotypic (99% negative). The significance of this finding is uncertain as atypical T-cell populations may be seen in reactive, T-CUS and neoplastic conditions.

CASE 14

Case 23-319 Description: Peripheral blood in EDTA, submitted for enlarging mediastinal mass concerning for lymphoma

Panel and instrumentation: TRBC1/CD26/CD8/CD3/CD7/CD4/CD56/CD2/CD5/CD45 on 10C Navios, specimen was stained first then lysed with OptiLyse and washed

Plots with gating strategy:

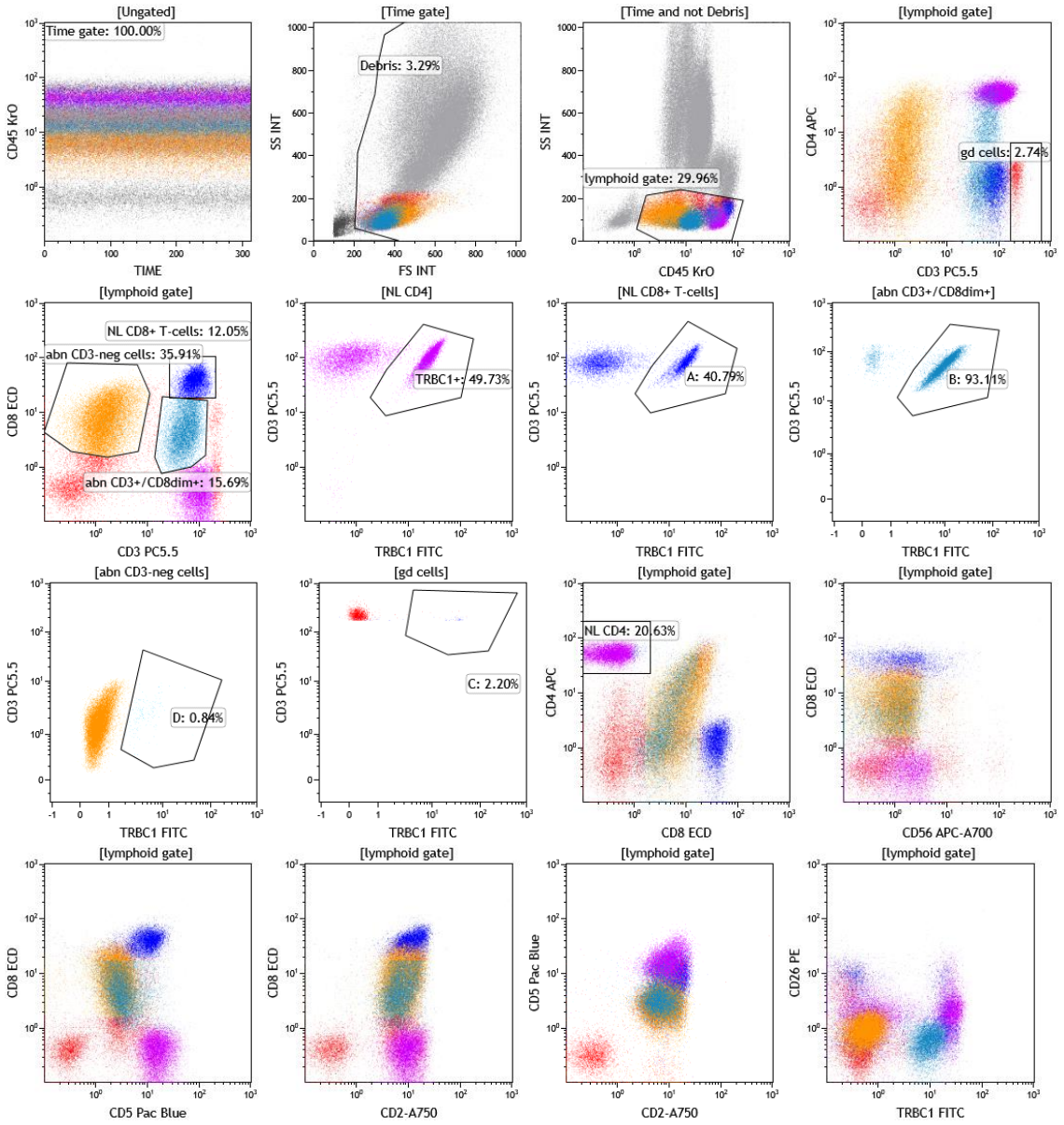

Abnormal Phenotype: CD2+, surface CD3+ (small subset), cyCD3+, CD4+ (spectrum), CD5+ (dim), CD7++, CD8+, CD10+ (dim), CD34 mostly neg, CD38+, CD56-neg, nTdT mostly neg, cyMPO-neg and cyCD79a-neg.

Percent abnormal of total pb cells: 15% (5% TRBC1+)	**Absolute#:** 1,186/cmm (TRBC1+)

Clinical Correlation: Abnormal T-cells in pb were confirmed in concurrent lymph node biopsy as T-lymphoblastic leukemia/lymphoma

Interpretation: The CD3+ subset of the abnormal phenotype shows TRBC1 monotypic expression (93% positive)

CASE 15

Case 23-0296 Description: Gastric folds EUS FNA, submitted for Pancreatitis, abnormal LFT's, jaundice

Panel and instrumentation: TRBC1/CD26/CD8/CD3/CD7/CD4/CD56/CD2/CD5/CD45 on 10C Navios, specimen was stained and washed

Plots with gating strategy:

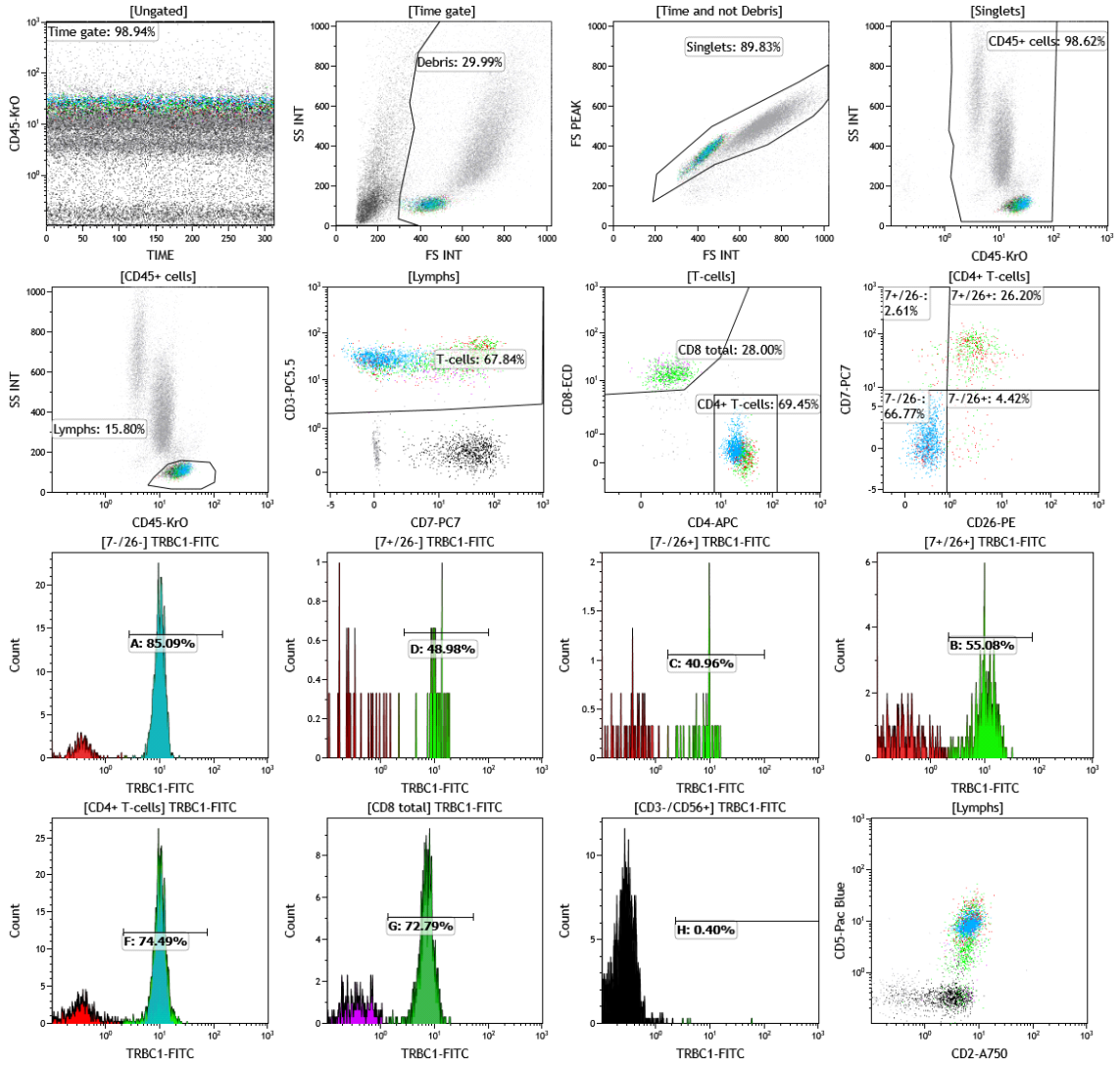

Atypical Phenotype: CD2+, CD3+, CD4+, CD5+, CD7-neg, CD8-neg, CD26-neg and CD56-neg

Percent abnormal of lymphoid population: 33% | **Absolute#:** NA

Clinical Correlation: Gastric cancer, neoplasm of uncertain behavior of skin, skin lesions

Interpretation: Atypical T-cell population of uncertain significance. TRBC1 expression on the atypical phenotype appears positive (85%) but does not show definitive evidence of monotypic expression. The significance of this finding is uncertain as atypical T-cell populations may be seen in reactive, T-CUS and neoplastic conditions.

CASE 16

Case 23-139 Description: Bone marrow in NaHeparin, submitted for hx of T-PLL

Panel and instrumentation: TRBC1/CD26/CD8/CD3/CD7/CD4/CD56/CD2/CD5/CD45 on 10C Navios, specimen was bulk-lysed, stained and washed

Plots with gating strategy:

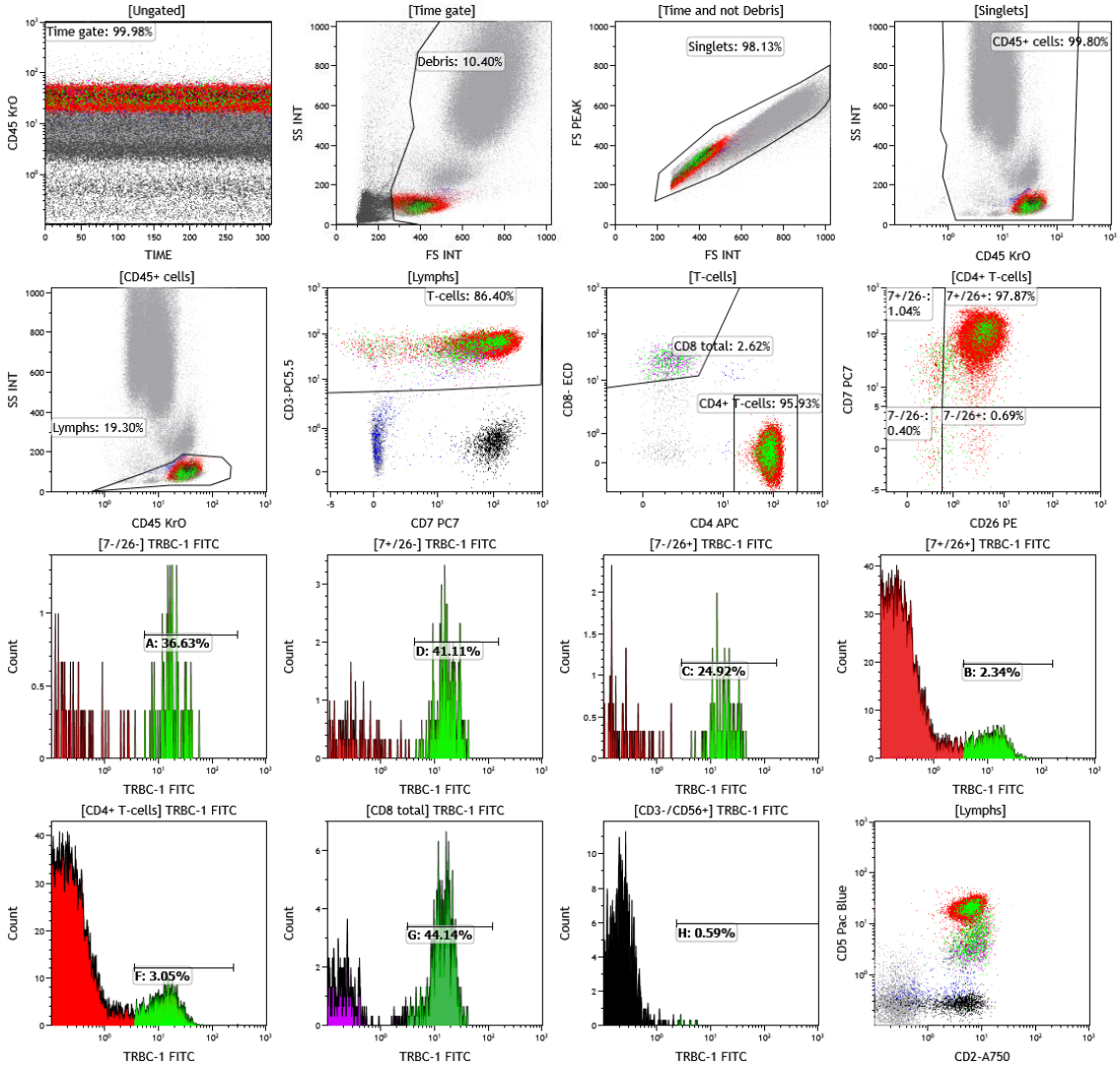

Abnormal Phenotype: CD2+ (decreased), CD3+, CD5+ (bright), CD7+, CD4+, CD8-neg, CD10-neg, CD26+ and CD38+

Percent abnormal of total bm cells: 15.4%	**Absolute#:** NA

Clinical Correlation: CD4+ T-cell Lymphoma B/BM, abnormal FISH (22% of nuclei had a rearrangement involving TCL1A, which usually represents an inv(14) or t(14;14). Rearrangements of TCL1A are typically associated with T-cell Prolymphocytic Leukemia .

Interpretation: The abnormal phenotype shows TRBC1 monotypic expression (98% negative)

CASE 17

Case 22-2313 Description: Peripheral blood in EDTA, submitted for leukocytosis

Panel and instrumentation: TRBC1/CD26/CD8/CD3/CD7/CD4/CD56/CD2/CD5/CD45 on 10C Navios, specimen was stained first then lysed with OptiLyse and washed

Plot with gating strategy:

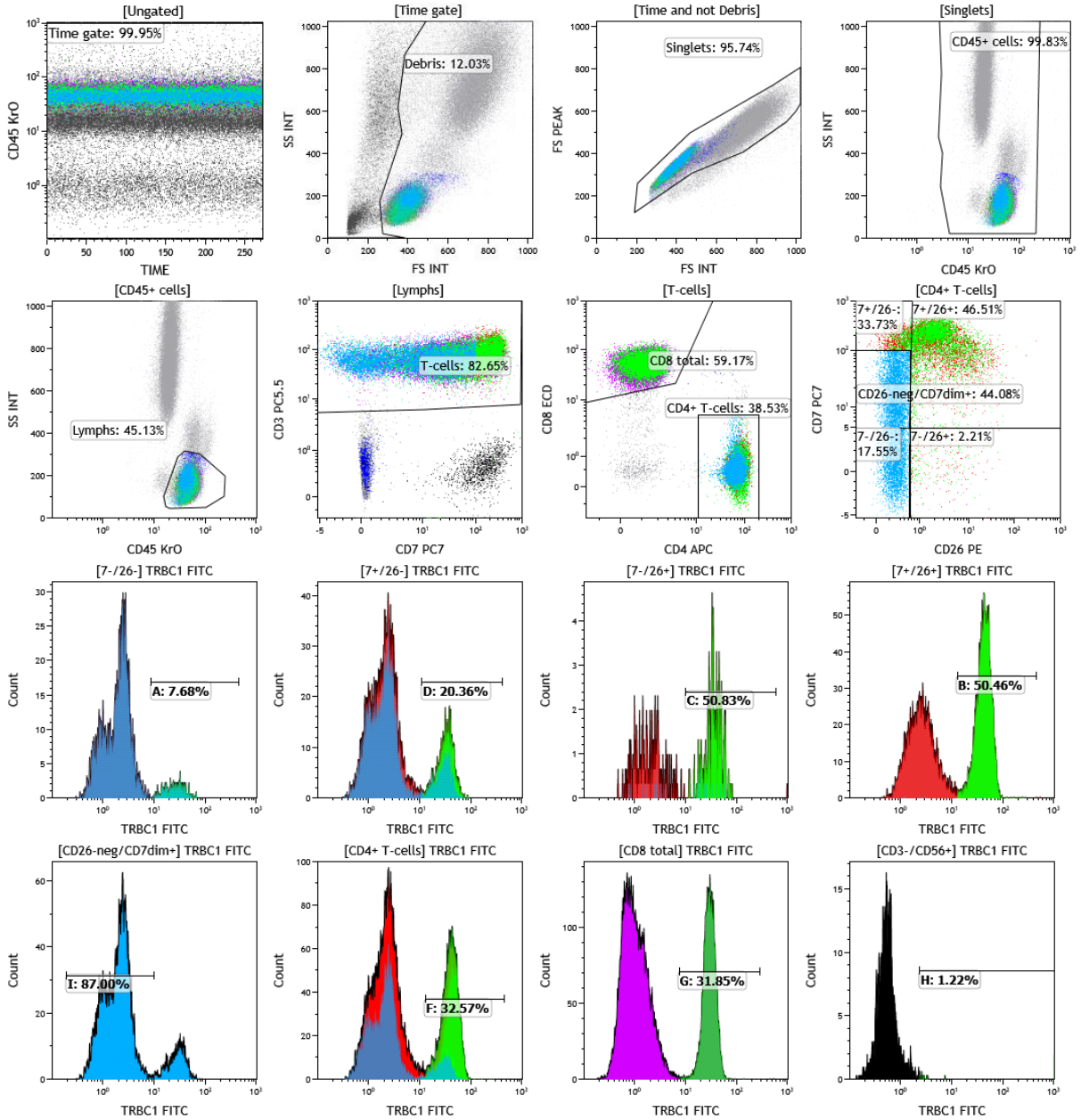

Atypical Phenotype: CD2+, CD3+, CD4+, CD5+, CD7-neg to dim+, CD8-neg, CD26-neg and CD56-neg.

Percent abnormal of total pb cells: 9% | **Absolute#:** 1,477/cmm

Clinical Correlation: Autoimmune hepatitis, Lupus, RA

Interpretation: TRBC1 expression appears negative to dim+ and does not show definitive evidence of monotypic expression. The significance of this finding is uncertain as atypical T-cell populations may be seen in reactive, T-CUS and neoplastic conditions.

CASE 18

Case 22-2024 Description: Peripheral blood in EDTA, submitted for progressive lymphocytosis

Panel and instrumentation: TRBC1/CD26/CD8/CD3/CD7/CD4/CD56/CD2/CD5/CD45 on 10C Navios, specimen was stained first then lysed with OptiLyse and washed

Plots with gating strategy:

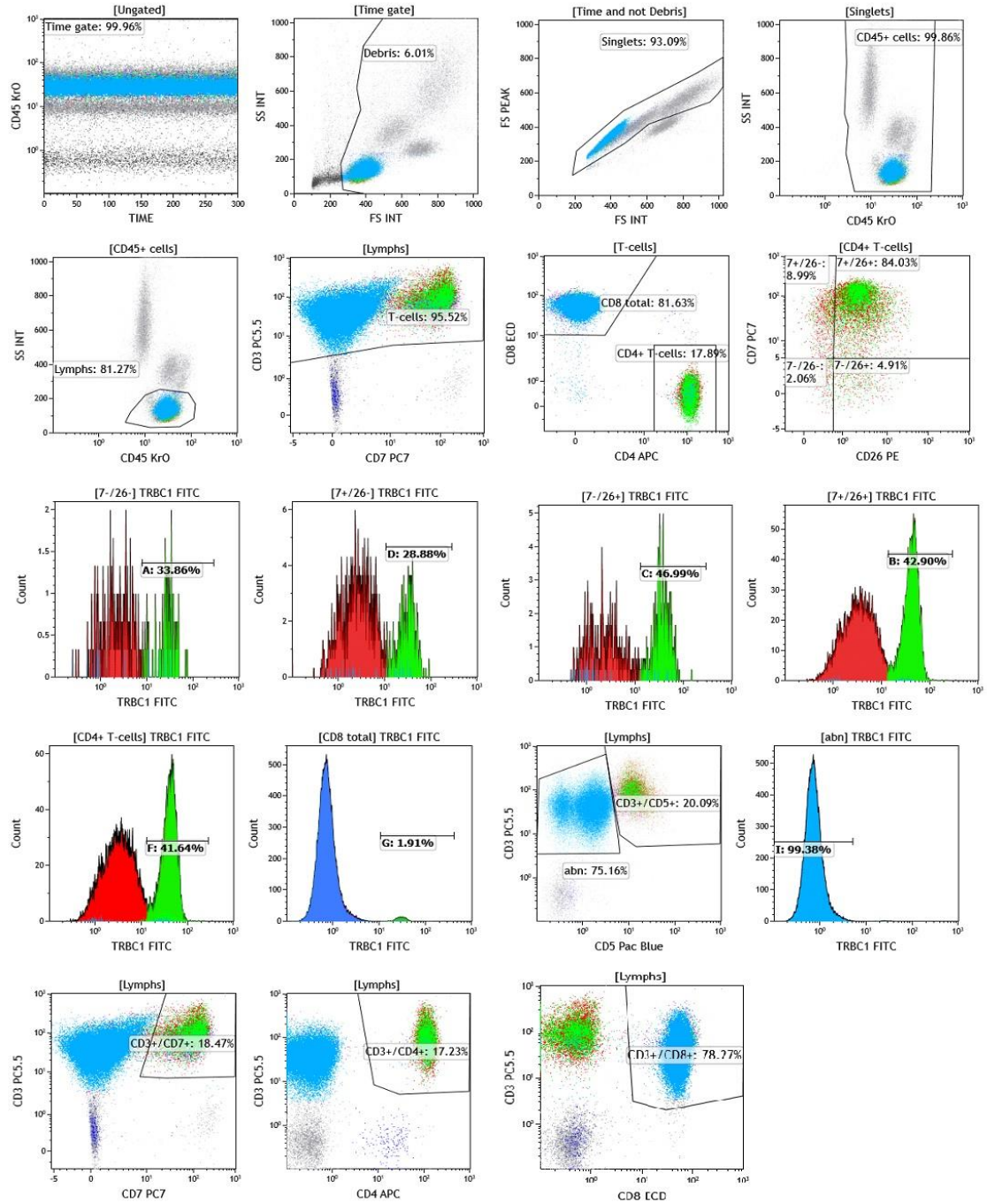

Abnormal Phenotype: CD45+, CD2+, CD3+, CD4-negative, CD5dim+, CD7-negative, CD8+, CD56dim+ and CD57-negative.

Percent abnormal of total pb cells: 60.8%	**Absolute#:** 3,873/cmm

Clinical Correlation: Polyarthritis with T-cell LPD, Chronic LGL, T-cell clonality by PCR-detected

Interpretation: The abnormal phenotype shows TRBC1 monotypic expression (99% negative)

CASE 19

Case Description: Blood in sodium heparin submitted for persistent mild lymphocytosis with a history of Granulomatosis with polyangiitis (GPA).
Panel and Instrumentation: Analyzed on 10C Navios after staining first and then lysis with ammonium chloride. γδ/αβ/CD7/CD5/CD8/CD4/CD2/CD56/CD57/CD3 TRBC1/CD1a/CD7/CD5/CD8/CD4/CD2/CD10/CD3/CD45

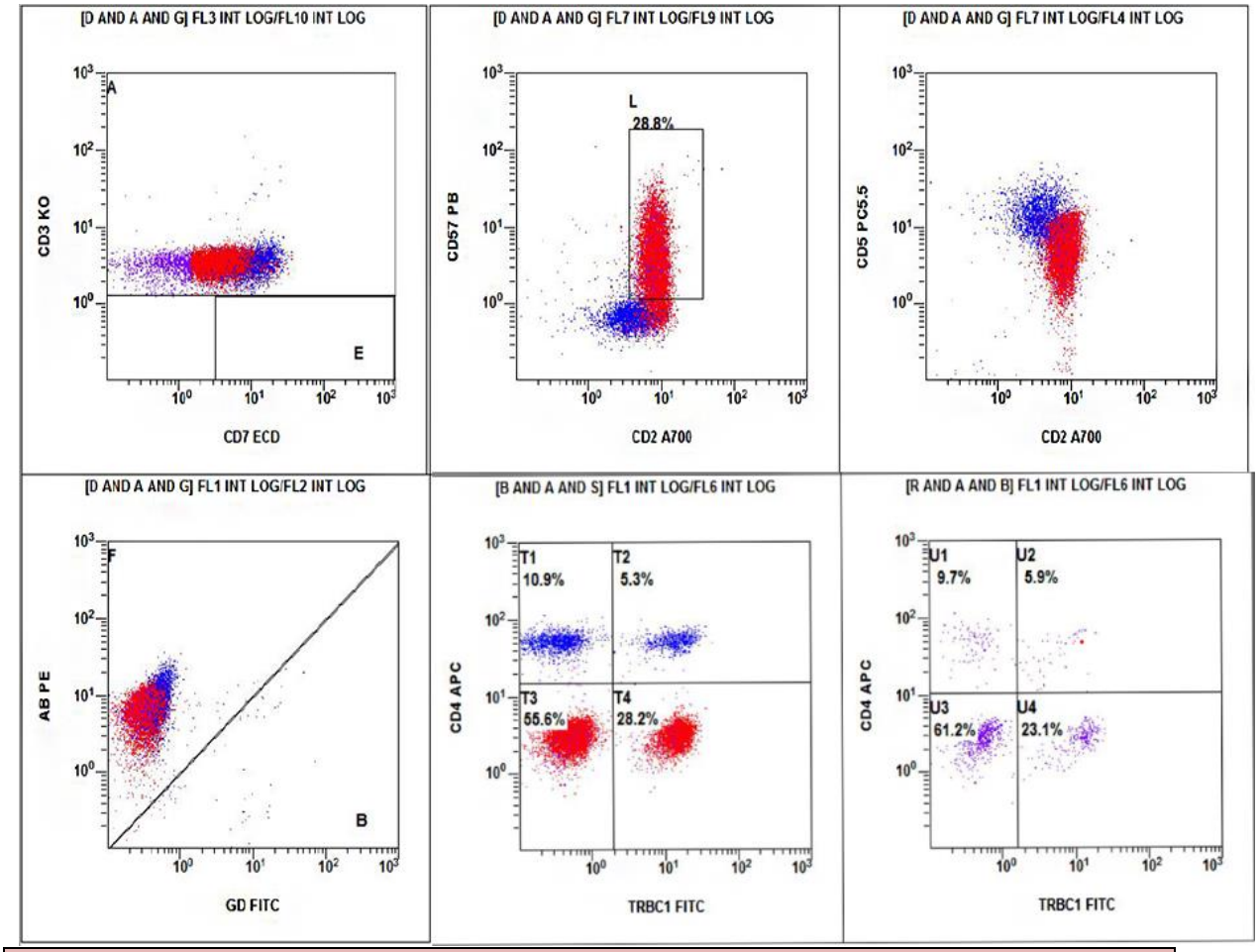

Phenotype: CD3+, CD8+, CD5^{dim}, CD7^{dim}, CD2+, CD57++, TRBC1 polytypic
Percent abnormal of lymphocytes: none
Interpretation: reactive T-LGL cells

CASE 20

Case Description: Pelvic soft tissue mass received in RPMI supplemented with fetal bovine serum from patient with splenomegaly and mesenteric, retroperitoneal, and pelvic lymphadenopathy.

Panel and Instrumentation: KAPPA/19, LAMBDA/19, CD20, CD5, CD19, CD200, CD23, CD71, CD10, CD45, TRBC1, CD1a CD7, CD5, CD8, CD4, CD2, CD10, CD3, αβ. Analyzed on 10C Navios. Specimen lysed and then stained. Clonal T-cell population (purple) and clonal B-cell population (green) identified.

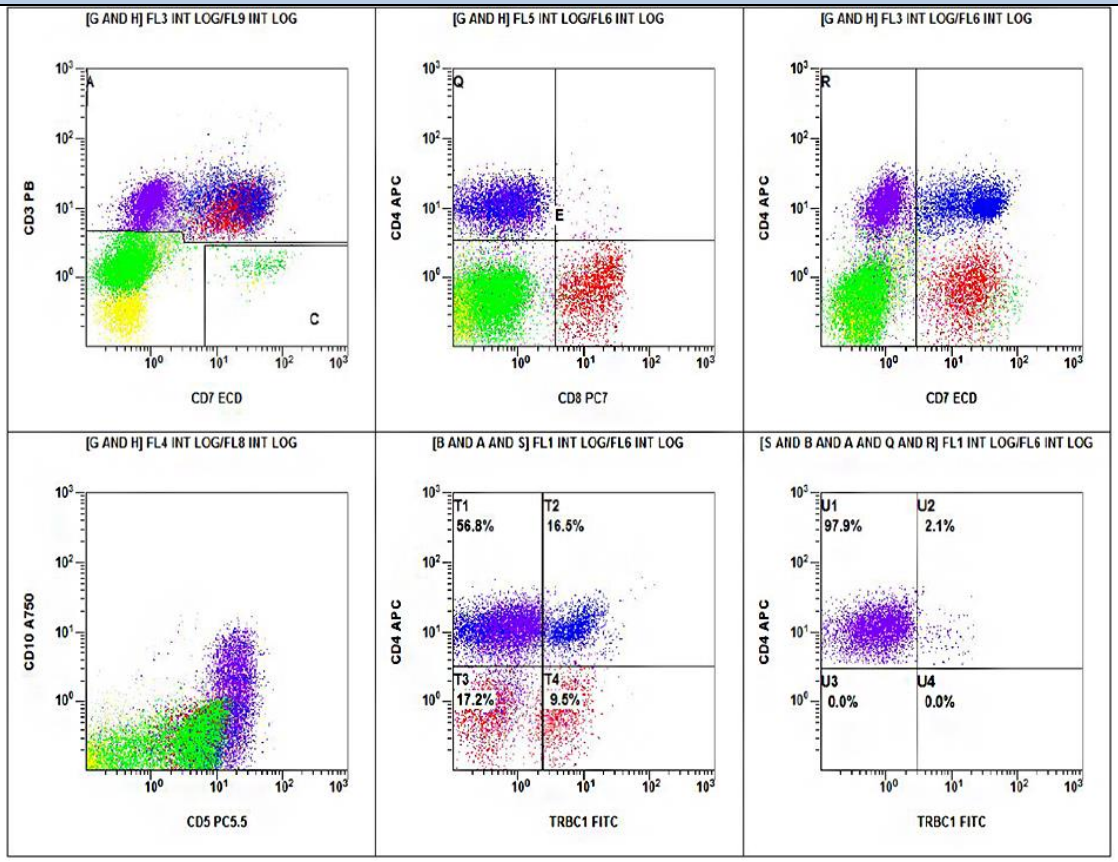

Phenotype: T-cell clone CD3+, CD4+, CD10^{dim}, CD5+, CD7-, TRBC1-

Percent abnormal of total lymphocytes (two clonal populations identified): T-cell clone 19% and B-cell clone with CLL/SLL phenotype 26%

Clinical Correlation: ATYPICAL T-CELL LYMPHOID INFILTRATE WITH FEATURES MOST COMPATIBLE WITH ANIGIOIMMUNOBLASTIC T-CELL LYMPHOMABACKGROUND INVOLVEMENT BY CHRONIC LYMPHOCYTIC LEUKEMIA/SMALL LYMPHOCYTIC LYMPHOMA (predominantly detected by flow cytometry)